

# Apocrine hidrocystoma appearing after Er:YAG laser treatment: a case report

Dr Hilary Brown<sup>1</sup>, Dr Sally De Zwaan<sup>2</sup>

1: Kotara Family Practice, Kotara, Australia

2: Department of Dermatology, John Hunter Hospital, New Lambton, Australia

Apocrine hidrocystomas are benign, cystic tumours arising from the apocrine sweat gland. They usually present as a solitary papule or nodule in the periorbital area and it is uncommon for multiple lesions to appear. We present a case of multiple apocrine hidrocystomas on the nasal dorsum which became apparent after ablative laser treatment. We also review the literature for apocrine hidrocystoma, including their clinical presentation, histopathological findings and treatment options.

**Key words:** Hidrocystoma · Apocrine Glands · Sweat Gland Neoplasm · Er:YAG Laser · Picosecond Alexandrite Laser

## Introduction

Apocrine hidrocystomas are benign, cystic tumours arising from the apocrine sweat gland. They usually present as a small, solitary papule or nodule and it is uncommon for multiple lesions to appear.

We present a case of multiple apocrine hidrocystomas on the nasal dorsum which became apparent after ablative laser treatment.

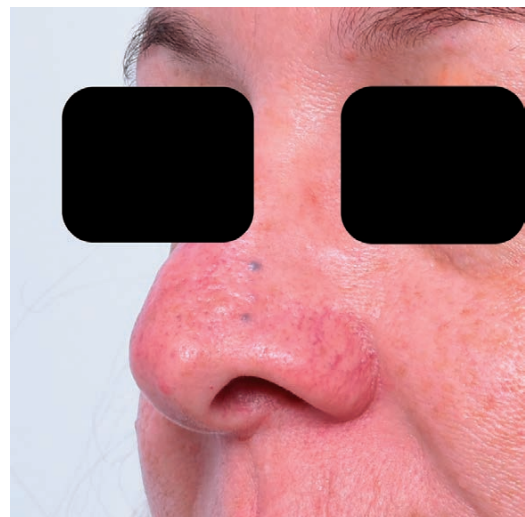## Case report

A 46-year-old woman presented with three small bluish papules on her nose which were noticed following Er:YAG laser treatment (**Figure 1**). The papules were arranged in a linear distribution along the left side her nose and ranged from 1-3 mm in diameter. There were no surrounding skin changes and full hair, skin and nail examination revealed no other abnormalities including no syndromic features. The papules were asymptomatic and she was otherwise well.

One week prior to presentation she had a single treatment with Er:YAG laser (Sciton Profile) at 2940 nm (rate 2 Hz, 5 j/cm<sup>2</sup>, 4mm scanner, 50% overlap, 1-2 pass-

es) to the whole of the nasal dorsum. The treatment was intended to cosmetically improve a scar on the right side of her nose from a previous basal cell carcinoma excision.

She has a past history of two basal cell carcinomas and one squamous cell carcinoma in-situ on the nose. These had been successfully treated with surgical exci-



**Figure 1:** Three bluish papules can be seen on the nasal dorsum following Er:YAG laser treatment

### \*Addressee for Correspondence

Dr Hilary Brown, FRACGP

ORCID <https://orcid.org/0000-0003-1530-8465>

hmebrown@gmail.com

Kotara Family Practice PO Box 256, Kotara, NSW 2289, Australia +61 410 636 332

Received date: November 4th, 2019

Accepted date: November 25th, 2019

J-STAGE Advance Publication Date: April 18th, 2020

## CASE REPORT

sions, one course of topical imiquimod and two courses of topical 5-fluorouracil to reduce the risk of recurrence and further carcinomas.

The photos taken prior to her laser treatment were reviewed (**Figure 2**), and it was noted that the three small blue papules were subtly present prior to the use of laser, but not noticed by the patient or cosmetically significant. In her pre-treatment photos, however, the papules appeared to be deeper in the dermis and were less apparent.

The three lesions were treated with two sessions of picosecond alexandrite laser (PicoSure Cynosure) at 755 nm (rate 10 Hz,  $3.25 \text{ J/cm}^2$ - $4.07 \text{ J/cm}^2$ , 5 passes, spot size 2.8-2.5mm) without any improvement. Following this, the largest of the three lesions was excised with a 2mm punch biopsy for diagnosis and treatment.

Histopathological examination showed a cystic body within the dermis lined by a bland bilayer of cuboidal epithelium with some apical snouting consistent with apocrine hidrocystoma. The overlying epidermis showed no significant abnormality. There was no evidence of significant squamous atypia, atypical melanocytic proliferation or malignancy (**Figure 3**).

The patient elected not to treat the remaining two lesions as they were smaller and not significant symptomatically or cosmetically.

### Discussion

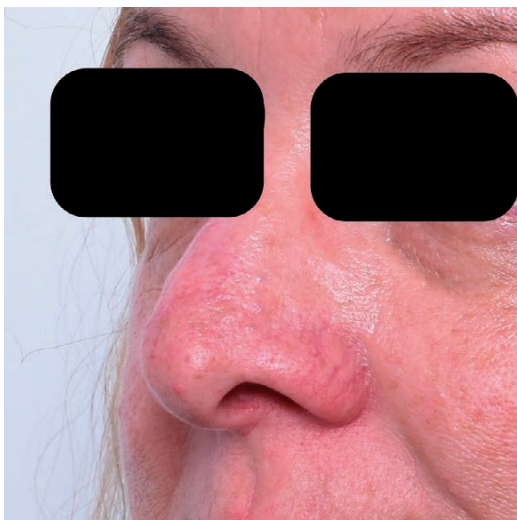Apocrine hidrocystoma are rare, cystic tumours, however, the exact prevalence is unknown. They are most common in adults aged 30-70 years old and have an equal presentation in men and women and rarely present in children and adolescents<sup>1</sup>.

Most patients present with an asymptomatic, solitary

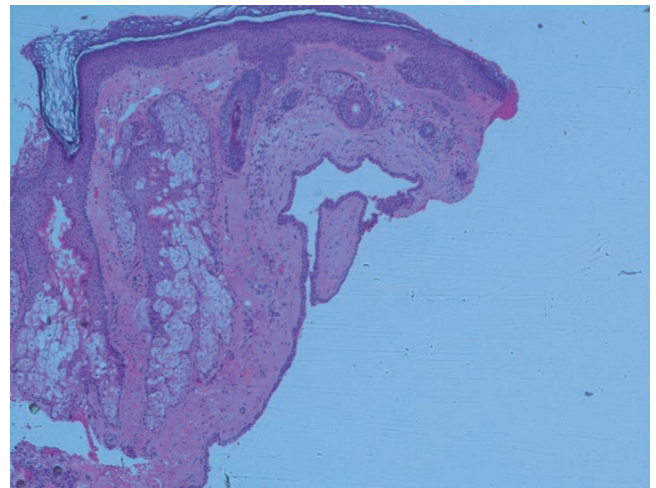
papule or nodule and occasionally patients may develop multiple lesions. The lesions are slow to grow and tend to persist. They usually occur in the periorbital region<sup>2</sup>, however, they can appear in any part of the body where apocrine sweat glands are found<sup>3</sup>. On clinical examination, the lesions appear as dome-shaped, translucent papules or nodules with a smooth surface and can be any colour from skin-coloured to blue to black. Dermoscopy may show a homogenous pale grey or bluish area, whitish cotton wool-like structures, linear vessels, or non-constant focal brown-orange areas<sup>3</sup>.

Differential diagnoses include eccrine hidrocystomas, epidermal inclusion cysts, syringomas, mucoid cysts, basal cell carcinoma, melanoma, molluscum contagiosum, blue naevus, haemangiomas and lymphangiomas<sup>1,4</sup>.

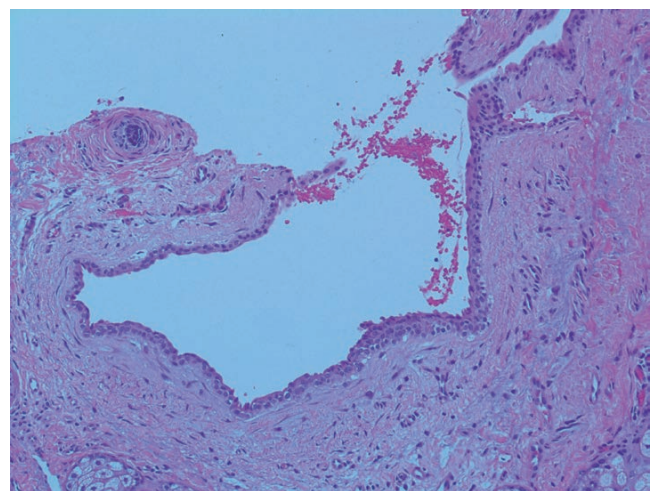
The aetiology and pathogenesis of apocrine hidrocystoma is unknown. It has been proposed that trauma



**Figure 2:** Three very small papules can be seen on the nasal dorsum prior to laser treatment



**Figure 3 (A):** Histopathology showing a cystic body expanding the dermis at 20x magnification



**Figure 3 (B):** Histopathology showing a bland bilayer of cuboidal epithelium lining the cyst with some hints of apical snouting at 20x magnification

or an inflammatory process results in obstruction of the sweat duct just above the glandular groove in the deep dermis leading to the development of an apocrine hidrocystoma<sup>4,5</sup>. There are no reports of these lesions arising following treatment with topical imiquimod or topical 5-fluorouracil. Cases of multiple apocrine hidrocystomas may be associated with rare ectodermal dysplasia syndromes such as Goltz-Gorlin syndrome and Schopf-Schulz-Passarge syndrome.

The diagnosis of apocrine hidrocystoma is made on histopathological examination. There is a unilocular or multilocular cyst in the dermis which is lined by three layers: a double cellular base, an outer layer of cubic myoepithelial cells which form intracavitary papillary digitations, and an internal layer of secreting cylindrical cells with an eosinophilic cytoplasm and characteristic decapitation secretory prominence. There may also be epithelial hyperplasia with intra-cystic papillary proliferation.

Treatment for apocrine hidrocystomas is not required as these are benign lesions. However, they are often removed for cosmetic purposes. Most lesions are treated with surgical excision. Needle puncture can be used however the lesions will frequently recur<sup>3</sup>. Other treatment options include electrocoagulation, trichloroacetic acid, cryosurgery, botulinum toxin A, carbon dioxide laser, and other laser treatments<sup>6</sup>.

Our patient presents with multiple apocrine hidrocystomas which were present following treatment for non-melanoma skin cancers and became more apparent after ablative laser treatment. Further studies may help to elucidate the possible association of these lesions with the trauma of surgical and topical chemotherapy to the involved skin. These lesions should be carefully looked for prior to laser therapy so that the patient may be informed that they may become more noticeable following ablative laser therapy.

**References**

- 1: Sarabi K, Khachemoune A. Hidrocystomas – A Brief Review. *MedGenMed.* 2006; 8(3):57
- 2: May C, Chang O, Compton N. A giant apocrine hidrocystoma of the trunk. *Dermatol Online J.* 2017 Sep 15;23(9)
- 3: Hafsi W, Badri T. Apocrine hidrocystoma. [Updated 2019 May 2]. In: *Stat Pearls.*Treasure Island (FL): StatPearls Publishing; Jan 2019 accessed at <https://www.ncbi.nlm.nih.gov/books/NBK448109/>
- 4: Resende IA, Lassari PM, Mandelbaum SH et al. Multiple apocrine hidrocystomas: a florid presentation. *An Bras Dermatol.* 2019 Mar-Apr;94(2):247-248
- 5: Smith RJ, Kuo IC, Reviglio VE. Multiple apocrine hidrocystomas of the eyelids. *Orbit* 2012 Apr;31(2):140-2
- 6: Bordelon JR, Tang N, Elston D et al. Multiple apocrine hidrocystomas successfully treated with botulinum toxin A. *Br J Dermatol* 2017 Feb;176(2):488-490

**Acknowledgments**

The authors would like to acknowledge Sarah Relic and Dr Vicki Howard for their assistance in preparing this manuscript.

**Financial support**

The authors declare they did not receive any financial support or funding in writing this report.

**Conflict of Interest Statement**

The authors declare no conflict of interest.