

## Monitoring the effectiveness of nanosecond laser for the treatment of port-wine stain patients using non-invasive imaging systems

Cheng-Han Jhan,<sup>1</sup> Ana Elena Aviña,<sup>2,3</sup> Tzu-Sen Yang,<sup>4,5</sup> Yu-Fan Chiang,<sup>6</sup>  
Cheng-Jen Chang<sup>4,5,7,8,9</sup>

<sup>1</sup>Department of Surgery, Taipei Medical University Hospital, Taipei Medical University, Taiwan; <sup>2</sup>International Ph.D. Program in Medicine, College of Medicine, Taipei Medical University, Taiwan; <sup>3</sup>Center for Vascularized Composite Allotransplantation, Chang Gung Memorial Hospital, Taoyuan, Taiwan; <sup>4</sup>Graduate Institute of Biomedical Optomechatronics, Taipei Medical University, Taiwan; <sup>5</sup>TMU Research Center of Cancer Translational Medicine, Taipei Medical University, Taiwan; <sup>6</sup>Medical School, University of Queensland, Brisbane, Australia; <sup>7</sup>Department of Plastic Surgery, Taipei Medical University Hospital, Taipei Medical University, Taiwan; <sup>8</sup>School of Medicine, College of Medicine, Taipei Medical University, Taiwan; <sup>9</sup>Department of Plastic and Reconstructive Surgery, Chang Gung Memorial Hospital, Chang Gung University, Taipei, Taiwan

### ABSTRACT

A variety of lasers have been used to treat port-wine stain (PWS) birthmarks, however, all of them carry the risk of adverse effects. Our objective was to assess the effectiveness and safety of nanosecond (ns) laser treatment for PWS patients using non-invasive images. This study included 20 PWS patients, whose ages ranged from one to sixteen years. A nanosecond laser ( $\lambda=595$  nm;  $\tau_p=2$  ns), with a spot size of 5 mm, and parameters of 0.2-0.3 J/cm<sup>2</sup>, 5 Hz, was used in three passes. The infrared thermal imager aided in determining the optimal laser dosage and preventing side effects. The primary efficiency was evaluated using a DermaSpectrometer, and patients were followed up after one week, four weeks, three months, and twelve months. The infrared thermal images of skin surface temperature assessment in the first ten seconds were recorded after the maximal energy density 0.3 J/cm<sup>2</sup> treatment. The thermal wave equation and Penne's bioheat transfer equation ranged from 32.4±0.1 to 33.8±0.2°C, 32.6±0.1 to 34.7±0.3°C (baseline skin surface temperature - 32.4±0.3°C) respectively. Transient hyperpigmentation appeared in 5% (n=1) of the 20 patients, but it resolved spontaneously within three months. There was no evidence of permanent hypopigmentation or scarring. The DermaSpectrometer revealed a 30% reduction in Hb-index three months after a single treatment. The infrared image instrument is helpful in determining the optimum laser dosage. For the treatment of PWS patients, a nanosecond pulsed laser at 595nm was effective and safe.

**Key words:** laser therapy; port-wine stains; spectrophotometry; thermography.

#### Corresponding author:

Ana E. Aviña, International Ph.D. Program in Medicine (IGPM), College of Medicine, Taipei Medical University, 250 Wuxing St., Taipei 11031, Taiwan. Rear Building, 7<sup>th</sup> Floor, Section C. Telephone: +886-2-27361661, Ext. 3119; Fax: +886-2-2736-9438. E-mail: d142111012@tmu.edu.tw

Received: 6 September 2023..  
Accepted: 18 October 2023.

## Introduction

A port-wine stain (PWS) is a vascular abnormality of the dermis that develops since birth.<sup>1-3</sup> PWSs are clinically relevant, and since two-thirds of these deformities occur on the face, they should be seen as an illness with potentially terrible psychological and physical consequences, rather than just a cosmetic issue. The unpleasant reaction of people to a “marked” individual has a detrimental impact on almost all patients’ personality development areas.<sup>4-6</sup> PWSs appear as light pink macules in infancy, but the lesions gradually deepen to scarlet purple; in addition to the pigment, many patients’ facial features are also severely disfigured by the following enlargement of underlying soft tissue and bone.<sup>7</sup> The histopathology of this vascular abnormality reveals a normal epidermis covering an aberrant plexus of subsurface blood vessels in the upper dermis.<sup>8</sup> Until now, the treatment options for PWSs have been cosmetic cover-up, skin grafting, ionizing radiation, dermabrasion, cryosurgery, tattooing, and electrotherapy, but none of those alternatives has been able to achieve aesthetically acceptable results. With the discovery of lasers and their capacity to selectively target PWS blood vessels, a promising therapeutic option for the clinical management of these patients became available. Argon laser, the first one oriented to the treatment of vascular malformations, primarily used to remove PWSs,<sup>9,10</sup> was also effective in treating even hypertrophic nodules caused by highly thickened PWSs. Following the introduction of the argon laser into clinical usage, additional specialized lasers for the treatment of vascular malformations have been developed, but scarring has been a concern with all of them,<sup>10</sup> including argon, CO<sub>2</sub>, and Neodymium-Doped Yttrium Aluminum Garnet (Nd:YAG). Out of all the available options, Pulsed Dye Laser (PDL) generated the greatest clinical outcomes with the lowest occurrence of side effects. The yellow light emitted by the PDL is preferentially absorbed by hemoglobin, allowing for more selective destruction of the upper dermal dilated ectatic capillaries. However, in the laser treatment of patients with PWSs, the clinical goal is to maximize thermal damage to targeted vessels, while minimizing non-specific injury to the overlying epidermis. Flashlamp-Pulsed Dye Lasers (FLPDL), with wavelengths ranging from 585 to 600 nm, and cryogen spray cooling are now suitable options for selective photothermolysis.<sup>11-24</sup>

According to diverse studies, the use of nanosecond (ns) lasers has significant implications for the treatment of

patients with hypervascular lesions such as post-acne erythema, inflammatory acne, facial flushing, and rosacea, among others.<sup>23,24</sup> Our goal was to use noninvasive images to evaluate the efficacy of nanosecond laser treatment for PWS patients. The primary efficacy metric was a quantitative assessment of blanching responses using a DermaSpectrometer (Cortex Technology, Hadsund, Denmark) to calculate the hemoglobin index. Safety for each patient was also assessed, intentionally looking for any adverse effects.

## Materials and Methods

The Institutional Review Board (IRB) approved the study protocol with the ID number 102-3062B. At the time of study enrollment, all patients and/or their legal guardians signed the IRB-approved consent form, and a multidisciplinary consultation was held during the first visit, in which the patient and family were informed that the laser treatment could entail multiple treatments over a period of months and that the average duration of each treatment would be determined both by the involved area(s) and by the severity of PWS. In the same way, the patients learned about the treatment’s discomfort, the type of skin reaction to be expected, the healing time, and the degree of blanching. All patients provided informed consent after the investigational nature of the procedure was fully explained. Photographic documentation, age, gender, and the severity of the PWS were the information collected to assess each patient.

The Classification of Severity was listed as follows: i) Severity 1: a) faint, barely discernible borders plus, b) well-defined borders with areas of normal skin interspersed within the lesion; ii) Severity 2: a) well-defined borders, uniform lesion with no areas of normal skin plus, b) raised or thickened lesion plus nodularity or hypertrophy of the involved anatomical structure.

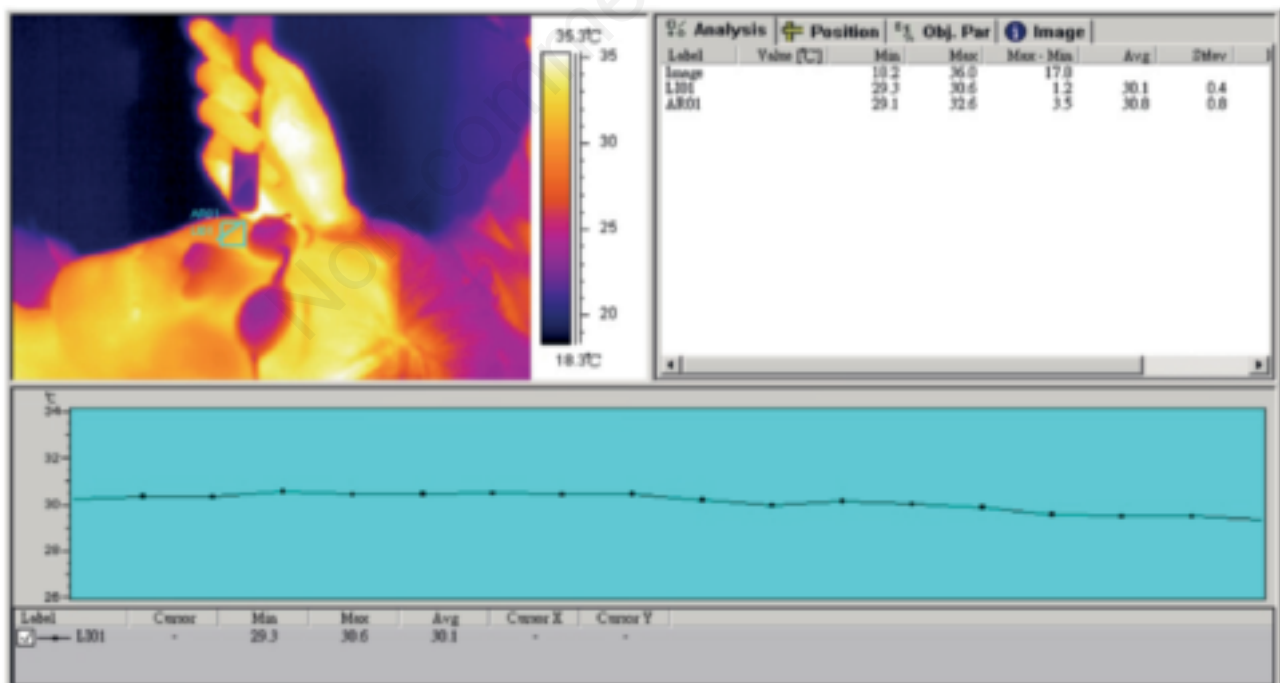
Our group recommends beginning laser therapy when the patient is one year old; before that age, the treatment is reserved for the most severe cases. In this study, all patients were treated as outpatients, without the use of local or general anesthesia. Lidocaine/prilocaine cream (EMLA®) was avoided except in children aged one to ten. The reason for this was that it causes vessel vasodilation, which reduces vessel response to laser treatment. Fortunately, the laser pulse is often well tolerated, with most patients describing it as a mild to moderately uncomfortable feeling akin to a

“rubber band snapping on the skin” or a “stinging sensation.” Therefore, small lesions can be treated in a single session, but multiple partial treatments are frequently necessary for bigger lesions.

In our study, test sites were allocated using computer-generated randomization. The lesion test sites were subjected to a single treatment with the PicoPlus (Lutronic Co. Billerica, MA, USA) laser system (wavelength  $\lambda=595$  nm; spot size 5 mm,  $\tau_p=2$  ns) to find the energy density that would generate the optimal therapeutic response (blanching), on portions of a big lesion that were indicative of the patient’s whole congenital vascular malformation, we analyzed numerous test regions at successive energy densities beginning with  $0.2 \text{ J/cm}^2$ . Each consecutive test area’s energy was increased by  $0.1 \text{ J/cm}^2$  at a time, up to a maximum of  $0.3 \text{ J/cm}^2$ . The testing zones were treated with 5 Hz, three passes at each energy density. The areas overlapped by 25% to 33% of the beam diameter. This was best performed by sliding the laser handpiece methodically across the lesion, treating neighboring regions in sequence. We predicted the skin temperature distribution in nanosecond laser therapy for PWSs patients using an infrared thermal imaging device (ThermaCAMTMS60, FLIR System, Danderyd, Sweden) to prevent thermal harm caused

by the laser. Real-time imagery and skin temperature variations were recorded (Figure 1). The effects of temperature distributions on energy variance were investigated.<sup>11</sup> Data from the infrared thermal imaging instrument were entered both into the analytic solutions of the thermal wave equation and Penne’s bioheat transfer equation, and the results obtained were compared.

Once the optimal energy density for lesion therapy was determined, the treatment of the whole lesion was done with the appropriate light dosage. Over the next six to eight weeks, the lesions were anticipated to lighten and become inconspicuous progressively. At each patient’s follow-up visit, the primary effectiveness measure was the quantitative evaluation of blanching responses using a DermaSpectrometer to calculate the Hemoglobin (Hb)-index; in every assessment, five different measurements were taken for each test location and the results averaged. The given means are the averages of all twenty participants in the research. The Hb-indices of the test site blanching reactions were assessed before and after nanosecond laser therapy (after four weeks, three months, and twelve months). The individual in charge of taking the DermaSpectrometer measurements was blinded to the treatment previously provided and instructed to make each meas-



**Figure 1.** Measurements of the skin temperature distribution in nanosecond laser treatment for Port-Wine Stains (PWS) patients.

urement touching the skin but without applying pressure to the test site, to avoid measurement error.

In addition, the patients were continuously observed for the occurrence of any side effects. Each treatment group's safety was assessed by looking for any aberrant wound healing (blistering, scabbing, erosion), scarring, or dyspigmentation. Scarring on the test locations was characterized as a persistent elevated hypertrophic, depressed, or atrophic skin texture. Dyspigmentation was considered as a temporary (resolving within three months of therapy) or permanent alteration in skin color on the test sites when compared to neighboring normal skin. Patients were examined for complications at the same time points as for the bleaching test: at four weeks, three months, and twelve months following therapy.

## Results

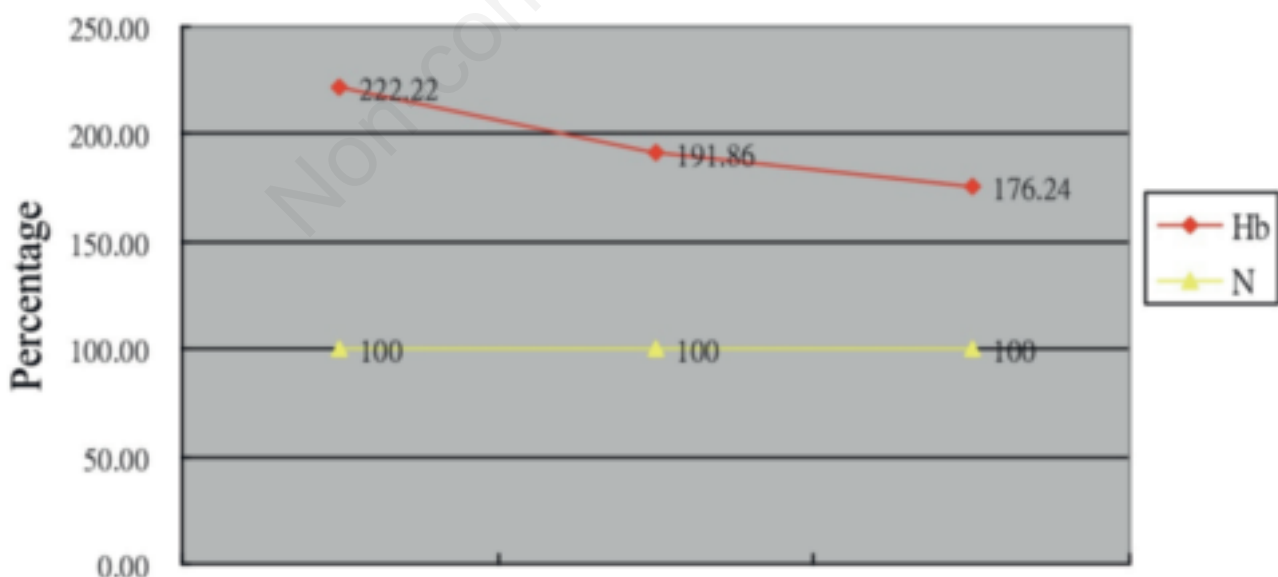
This study involved 20 PWS patients (eleven females and nine males) treated with the nanosecond laser over an 18-month period (March 2021 - July 2022). Patients' ages ranged from one to sixteen years, with an average age of 12.4 years. All of the patients were Asian. The following data were retrieved for every case: age, gender, and PWS severity.

For each patient, the infrared thermal image of skin sur-

face temperature assessment in the first ten seconds (s), both by the thermal wave equation and by Penne's bioheat transfer equation, ranged from  $32.4 \pm 0.1$  to  $33.8 \pm 0.2^\circ\text{C}$  and  $32.6 \pm 0.1$  to  $34.7 \pm 0.3^\circ\text{C}$ , respectively (baseline skin surface temperature  $-32.4 \pm 0.3^\circ\text{C}$ ) after the maximal energy density  $0.3 \text{ J/cm}^2$  treatment (Table 1).

The reported means of Hb-indices are the average values for all 20 patients enrolled in the study. Before laser treatment, the average percentage of Hb-indices of all PWSs was 250 (normal skin 100), while it was 222.22 at four weeks, 191.86 at three months, and 176.24 at twelve months after the nanosecond laser treatment (Figure 2). The DermaSpectrometer demonstrated that a 30% reduction of Hb-indices can be achieved twelve months after one treatment. The primary efficacy measure was the quantitative assessment of the blanching response score of PWS patients. There were clinically and statistically significant variations in blanching response scores before and after nanosecond laser therapy ( $p=0.05$ ) based on chi-squared analysis for the improvement of Hb-indices. In 5% ( $n=1$ ) of the 20 individuals, transient hyperpigmentation was seen. Within three months, the hyperpigmentation resolved spontaneously.

There was no evidence of permanent hypopigmentation or scarring. Our findings show that the use of a nanosecond laser to minimize the photothermal impact created during selective vascular photothermolysis, might lessen



**Figure 2.** The DermaSpectrometer demonstrated an average 30% reduction of Hb-index can be achieved 12 months after one treatment.

the occurrence of complications while providing a dependable result. (Figure 3, Figure 4).

## Discussion

When treating PWS, the FLPDL has generated the best clinical results, with the fewest adverse effects.<sup>9</sup> The favorable result can be related to the fact that the yellow light produced by the FLPDL can selectively damage cutaneous blood vessels; with a wavelength light of 575-600 nm, and

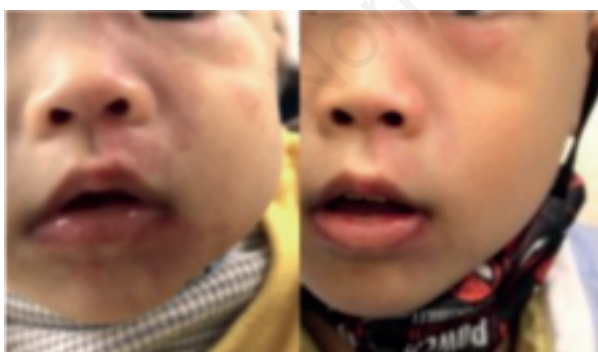**Table 1.** Skin surface temperatures were assessed using the thermal wave equation and Penne's equation for nanosecond laser treatment of the Port-Wine Stain (PWS) patients.

Time (second)	Skin surface temperature (°C)	
	Thermal wave equation	Penne's equation
1	32.6±0.2	34.1±0.3
2	33.8±0.2	34.7±0.3
3	33.7±0.3	34.5±0.2
4	33.5±0.3	34.2±0.3
5	33.3±0.3	33.9±0.4
6	32.9±0.1	33.7±0.1
7	32.8±0.2	33.5±0.2
8	32.7±0.1	33.2±0.1
9	32.6±0.2	32.8±0.2
10	32.4±0.1	32.6±0.1

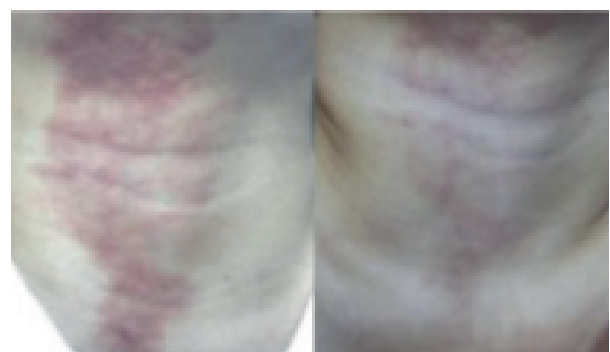Baseline skin surface temperature -32.4±0.3°C.

a pulse duration of milliseconds (ms) it is preferentially absorbed by hemoglobin (the primary chromophore in the blood) in the upper dermal ectatic capillaries.<sup>12-14</sup> The energy is transformed to heat, producing thermal damage and thrombosis in the vessels that have been targeted. The epidermis, on the other hand, is not completely spared due to melanin's partial absorption of energy that creates an optical barrier through which light must travel to reach the underlying blood vessels. The absorption of laser energy by melanin, if not regulated, generates localized heating in the epidermis, which can lead to lasting complications such as hypertrophic scarring or dyspigmentation. Furthermore, epidermal melanin lowers the quantity of light that reaches the blood vessels, reducing the amount of heat produced in the targeted PWS and resulting in inadequate blanching of the lesion. Unfortunately, for many lesions, the threshold for PWS is greater than the threshold for epidermal damage following laser treatment. As a result, epidermal injury is expected.

In the laser therapy of individuals with PWSs, the therapeutic goal is to maximize thermal damage to targeted arteries while minimizing non-specific harm to the overlying epidermis.<sup>25-27</sup> A proposed method for achieving this goal is to give a regionally selective epidermal temperature drop while leaving the temperature of deeper blood vessels unaltered. The term "spatially selective photocoagulation"<sup>28</sup> refers to the notion of giving epidermal protection while inflicting thermal harm in higher dermal vessels. This selective photocoagulation is necessary, since it is not possible to only lower the working tem-



**Figure 3.** A two-year-old boy with a Port-Wine Stains (PWS) on his left face and chin prior to laser therapy (left side). The result was evaluated as a significant blanching response 12 months after treatment with nanosecond laser (595 nm) using a spot size of 5 mm with an energy density of 0.3 J/cm<sup>2</sup>, 5 Hz, and three passes (right side).



**Figure 4.** A sixteen-year-old girl with a PWS on her neck: prior to laser therapy (left side); and three months after treatment with nanosecond laser (595 nm) using a spot size of 5 mm with an energy density of 0.3 J/cm<sup>2</sup>, 5Hz, and three passes (right side).



peratures because insufficient heat production inside the vessels is the primary cause of inadequate PWS blanching after FLPDL (millisecond pulse) treatment. Regardless of the number of treatment sessions, many attempts at low light doses will not attain and sustain the threshold temperatures required to damage large blood vessels permanently.

When employing the thermal wave equation to analyze thermal damage, the influence of the thermal relaxation time ( $\tau_r$ ) should be taken into account. Penne's equation ignores this component. The thermal relaxation time for general homogeneous materials is often relatively short, ranging from  $10^{-8}$ - $10^{-14}$  s. Except when the heat flux rate changes significantly, thermal waves have no discernible influence during heat transfer. The biological systems, on the other hand, are expected to last 20-30 s.<sup>15,16</sup> In a subsequent investigation, researchers conducted experiments on processed heat and reached the following result: 16 s.<sup>17</sup> Most biological tissue investigations now consider 20 s. As a result, the time in this investigation is also fixed at 20 s.

The use of a nanosecond (595 nm) laser has significant results for the treatment of PWS patients, but it is critical to understand the size of the target in proportion to the energy used for the best outcomes.<sup>29</sup> The appropriate degree of energy must be estimated in order to avoid harming neighboring tissue. The target chromophore size of PWS blood vessels ranges from 10  $\mu$ m to 200  $\mu$ m, and the  $\tau_r$  may be determined between 90  $\mu$ s and 5 ms. Nanosecond lasers outperform millisecond pulsed lasers in terms of microvascular damage and adverse effects.

Many physicians believe that 595 nm will penetrate deeper into the PWS blood vessels, leading to a more consistent photocoagulation. The absorption coefficient of blood, on the other hand, is a key element in 595 nm. In a previous study, our group investigated the effectiveness and safety of laser therapy at 595 nm wavelengths for PWS birthmarks.<sup>18</sup> The analysis consisted in that over a 3-year period, a group of 32 individuals with head or neck PWS birthmarks were treated with the Candela ScleroPLUS® (Wayland, MA, USA) pulsed dye laser ( $\lambda=595$  nm;  $\tau_p=1.5$  ms). Patients were exposed to 595 nm light doses ranging from 7 to 10 J/cm<sup>2</sup>. The quantitative assessment of the blanching response scores of 595 nm treated individuals served as the major effectiveness measure. The results and safety for PWS patients receiving 595 nm were both positive. In 37.5% (n=12) of the 595 nm treated individuals, transient hyperpigmentation

was seen, but in all cases faded after a year. There was no evidence of permanent hypopigmentation or scarring. That result points to the suitability of the 595 nm wavelength for treating PWS patients. Recent similar studies conducted in patients belonging to specific ethnicities have confirmed these encouraging findings.<sup>30-32</sup>

In the present research, we anticipated the skin temperature distribution in the therapy for PWS patients using an infrared thermal imaging device to prevent thermal harm caused by nanosecond laser (595 nm). The analytic solutions of the thermal wave equation were compared with those of Penne's bioheat transfer equation; the results showed that the nanosecond laser (595 nm wavelength; 2 ns pulse duration; spot size 5 mm, 5 Hz, three passes) when the energy densities remained higher than 0.3 J/cm<sup>2</sup> led to burn injury (if temperatures higher than 44°C) using both thermal wave and Penne's equations. However, the previous calculations indicate that under the situation of a large heat flow for a relatively short period, the forecast of the skin surface temperature given from Penne's equation is substantially greater than that calculated from the thermal wave equation. As a result, the thermal wave equation<sup>11,23-25</sup> may most likely predict the skin temperature distribution in PWS patients undergoing nanosecond laser therapy (Table 1).

The DermaSpectrometer was used to provide quantitative therapy outcomes of the vascular lesions. Light-emitting diodes produce light at two distinct wavelengths: 568 nm (green) and 655 nm (red). As a result, it may be used to determine oxyhemoglobin and melanin levels by measuring absorbed and reflected light at green and red wavelengths.<sup>26,27</sup> As previously indicated, test sites were allocated using computer-generated randomization, and the individual taking the DermaSpectrometer measurements was blinded to the treatment provided for the patient and instructed to make each measurement touching the skin but without applying pressure to the test site to avoid measurement error.

## Conclusions

We were able to monitor, by non-invasive means, the optimization of the thermal impact on targeted vessels, while avoiding adverse sequelae in the nanosecond laser therapy. For the treatment of pediatric PWS patients, a nanosecond pulsed laser at 595 nm provided a significant difference in the blanching test, pre and post-treat-

ment. The nanosecond laser can diminish the photothermal skin impact and the incidence of adverse effects related to the selective photothermolysis of vascular structures. Our findings must be investigated in larger samples (resulting in high power) with ethnically diverse conformation and standardized clinical practice patterns; therefore, more studies, particularly a multicenter controlled trial, are necessary.

**Authors' contributions:** all the authors made a substantive intellectual contribution. All the authors have read and approved the final version of the manuscript and agreed to be held accountable for all aspects of the work.

**Conflict of interest:** all authors declare that they have no conflicts of interest associated with this publication.

**Funding:** this project was supported by research grants awarded by Chang Gung Memorial Hospital (CMRPG33033, CMRP 821). This work was financially supported by the "TMU Research Center of Cancer Translational Medicine" from The Featured Areas Research Center Program within the framework of the Higher Education Sprout Project by the Ministry of Education (MOE) in Taiwan. This study was also supported by the Ministry of Science and Technology, Taiwan, under grants (MOST 111-2221-E-038-012-, MOST 111-2221-E-038-009-).

**Ethics approval and consent to participate:** the Institutional Review Board (IRB) approved the study protocol with the ID number 102-3062B. At the time of study enrollment, all patients and/or their legal guardians signed the IRB-approved consent form, and a multidisciplinary consultation was held during the first visit, in which the patient and family were informed that the laser treatment could entail multiple treatments over a period of months and that the average duration of each treatment would be determined both by the involved area(s) and by the severity of PWS. In the same way, the patients learned about the treatment's discomfort, the type of skin reaction to be expected, the healing time, and the degree of blanching.

**Availability of data and materials:** all data generated or analyzed during this study are included in this published article.

**Acknowledgments:** this manuscript was edited by Wallace Academic Editing. The authors gratefully acknowledge the assistance of Meng-Tsan Tsai Ph.D., Chih-Chung Yang, Ph.D., Graduate Institute of Electro-Optical Engineering, National Taiwan University, Taiwan, and Zhong Pin Chen, Ph.D., Michael Burns Ph.D., J. Stuart Nelson, M.D., Ph.D., Beckman Laser Institute and Medical Clinic, University of California, Irvine, California.

## References

1. Mulliken JB, Young AE, editors. Vascular Birthmarks: Hemangiomas and Malformations. Philadelphia, USA: Philadelphia WB Saunders. 1988.
2. Jacobs AH, Walton RG. The incidence of birthmarks in the neonate. *Pediatrics* 1976;58:218-22.
3. Pratt AG. Birthmarks in infants. *AMA Arch Derm Syphilol* 1953;67:302-5.
4. Kalick SM. Toward an interdisciplinary psychology of appearances. *Psychiatry* 1978;41:243-53.
5. Heller A, Rafman S, Zvagulis I, Pless IB. Birth defects and psychosocial adjustment. *Am J Dis Child* 1985;139:257-63.
6. Malm M, Carlberg M. Port-wine stain—a surgical and psychological problem. *Ann Plast Surg* 1988;20:512-6.
7. Geronemus RG, Ashinoff R. The medical necessity of evaluation and treatment of port-wine stains. *J Dermatol Surg Oncol* 1991;17:76-9.
8. Barsky SH, Rosen S, Geer DE, Noe JM. The nature and evolution of port wine stains: a computer-assisted study. *J Invest Dermatol* 1980;74:154-7.
9. Dixon JA, Gilbertson JJ. Argon and neodymium YAG laser therapy of dark nodular port wine stains in older patients. *Lasers Surg Med* 1986;6:5-11.
10. Dixon JA, Huether S, Roterger R. Hypertrophic scarring in argon laser treatment of port-wine stains. *Plast Reconstr Surg* 1984;73:771-9.
11. Ting K, Chen KT, Cheng SF, et al. Prediction of Skin Temperature Distribution in Cosmetic Laser Surgery. *Japanese Journal of Applied Physics* 2008;47:361-7.
12. Ashinoff R, Geronemus RG. Flashlamp-pumped pulsed dye laser for port-wine stains in infancy: earlier versus later treatment. *J Am Acad Dermatol* 1991;24:467-72.
13. Nelson JS, Applebaum J. Clinical management of port-wine stain in infants and young children using the flashlamp-pulsed dye laser. *Clin Pediatr (Phila)* 1990;29:503-9.
14. Nelson JS. Selective photothermolysis and removal of cutaneous vasculopathies and tattoos by pulsed laser. *Plast Reconstr Surg* 1991;88:723-31.
15. Chang CJ, Nelson JS. Cryogen spray cooling and higher fluence pulsed dye laser treatment improve port-wine stain clearance while minimizing epidermal damage. *Dermatol Surg* 1999;25:767-72.

16. Chang CJ, Kou CS. Comparing the effectiveness of Q-switched Ruby laser treatment with that of Q-switched Nd:YAG laser for oculodermal melanosis (Nevus of Ota). *J Plast Reconstr Aesthet Surg* 2011;64:339-45.
17. Mitra PP. Multiple wave-vector extensions of the NMR pulsed-field-gradient spin-echo diffusion measurement. *Phys Rev B Condens Matter* 1995;51:15074-8.
18. Chang CJ, Kelly KM, Van Gemert MJ, Nelson JS. Comparing the effectiveness of 585-nm vs 595-nm wavelength pulsed dye laser treatment of port wine stains in conjunction with cryogen spray cooling. *Lasers Surg Med* 2002;31:352-8.
19. Achauer BM, Chang CJ, Vander Kam VM. Nd: YAG laser treatment for facial hemangioma of infancy. *Ophthalmic Lit* 1997;1:4.
20. Achauer BM, Chang CJ, Vander Kam VM. Management of hemangioma of infancy: review of 245 patients. *Plast Reconstr Surg* 1997;99:1301-8.
21. Chang CJ, Hsiao YC, Mihm MC Jr, Nelson JS. Pilot study examining the combined use of pulsed dye laser and topical Imiquimod versus laser alone for treatment of port wine stain birthmarks. *Lasers Surg Med* 2008;40:605-10.
22. Hsiao YC, Chang CJ. Update on flashlamp pumped pulsed dye laser treatment for port wine stains (capillary malformation) patients. *Laser Ther* 2011;20:265-72.
23. Chang CJ, Yu DY, Chen HC, et al. Real-time photothermal imaging and response in pulsed dye laser treatment for port wine stain patients. *Biomed J* 2015;38:342-9.
24. Ting K, Chen K, Su Y, Chang C. Effects of thermal energy accumulations of multi-point heat sources in laser cosmetic surgery. *Proc. Inst. Mech. Eng* 2014;228:162-7.
25. Su Y, Chen K, Chang C, Ting K. Experiment and simulation of biotissue surface thermal damage during laser surgery. *Proc. Inst. Mech. Eng* 2015;231:581-9.
25. Tejasvi T, Sharma VK, Kaur J. Determination of minimal erythmal dose for narrow band-ultraviolet B radiation in north Indian patients: comparison of visual and Dermaspectrometer readings. *Indian J Dermatol Venereol Leprol* 2007;73:97-9.
27. Ramsing DW, Agner T. Effect of glove occlusion on human skin. (I). short-term experimental exposure. *Contact Dermatitis* 1996;34:1-5.
28. Buch J, Karagaiah P, Raviprakash P, et al. Noninvasive diagnostic techniques of port wine stain. *J Cosmet Dermatol* 2021;20:2006-14.
29. Fölster-Holst R, Shukla R, Kassir M, et al. Treatment Update of Port-Wine Stain: A Narrative Review. *J Drugs Dermatol* 2021;20:515-8.
30. Sabeti S, Ball KL, Burkhart C, et al. Consensus Statement for the Management and Treatment of Port-Wine Birthmarks in Sturge-Weber Syndrome. *JAMA Dermatol* 2021;157:98-104.
31. Sadeghinia A, Moghaddas S, Tavakolpour S, et al. Treatment of port wine stains with 595-nm pulsed dye laser in 27 pediatric patients: A prospective study in the Iranian population. *J Cosmet Laser Ther* 2019;21:373-7.
32. Khandpur S, Sharma VK. Assessment of Efficacy of the 595-nm Pulsed Dye Laser in the Treatment of Facial Port-Wine Stains in Indian Patients. *Dermatol Surg* 2016;42:717-26.