

## Effective optical zone after corneal lenticule extraction with the CLEAR femtosecond laser application

Antonio Leccisotti,<sup>1,2,3</sup> Stefania V. Fields,<sup>1</sup> Giuseppe De Bartolo,<sup>1</sup> Christian Crudale<sup>1</sup>

<sup>1</sup>Siena Eye Laser, Poggibonsi, Siena, Italy; <sup>2</sup>Scuola di Specializzazione in Oftalmologia, Università di Siena, Siena, Italy;  
<sup>3</sup>School of Biomedical Sciences, Ulster University, Coleraine, UK

### ABSTRACT

Laser vision correction of myopia induces an effective optical zone (EOZ) smaller than the programmed optical zone (POZ) by 16 to 26%. We evaluated the EOZ after corneal lenticule extraction for myopia with astigmatism  $\leq 1$  diopter (D) with a new femtosecond laser application (CLEAR), compared to POZ in a retrospective, consecutive, comparative case series study. Forty eyes of 40 patients underwent lenticule extraction with the Ziemer CLEAR® application; the control group was composed of 40 eyes of 40 patients receiving myopic femtosecond laser in situ keratomileusis (LASIK); EOZ was calculated on difference tangential maps at 6 months. For lenticule extraction, mean preoperative spherical equivalent (SE) was  $-6.03 \pm 2.48$  D; mean POZ was  $6.43 \pm 0.27$  mm; EOZ  $5.55 \pm 0.45$  mm; mean difference between POZ and EOZ was  $0.88 \pm 0.28$  mm ( $p=0.00$ ); the mean reduction of EOZ compared to POZ was  $13.60\% \pm 4.75$ ; a positive correlation between preoperative SE and percent reduction of EOZ was found ( $r=0.63$ ). For LASIK, mean preoperative SE was  $-5.89 \pm 2.14$  D; mean POZ was  $6.57 \pm 0.34$  mm; EOZ  $5.16 \pm 0.53$  mm; the mean difference between POZ and EOZ was  $1.41 \pm 0.35$  mm ( $p=0.00$ ); the mean reduction of EOZ compared to POZ was  $21.46\% \pm 5.20$ . The mean difference between EOZ of the 2 procedures was  $0.39$  mm ( $p=0.0008$ ). The mean difference between the reduction in optical zone (POZ-EOZ) of the 2 procedures was  $-0.53$  ( $p=0.00$ ). In conclusion, in myopia with low astigmatism, the CLEAR application for lenticule extraction provided a limited reduction in EOZ, compared with existing platforms. A positive correlation exists between corrected SE and reduction of the EOZ.

**Key words:** myopia; LASIK; lenticule extraction; femtosecond laser; optical zone.

#### Corresponding author:

Antonio Leccisotti, Largo Usilia 31, 53036 Poggibonsi (Siena), Italy.  
Telephone: +39.335.8118324  
E-mail: leccisotti@libero.it

Received: 10 September 2023.  
Accepted: 15 November 2023.

## Introduction

The effective optical zone (EOZ) (or functional optical zone, FOZ) is the corneal area providing functional visual quality after laser vision correction of refractive errors;<sup>1</sup> all laser techniques produce an EOZ smaller than the programmed optical zone (POZ), possibly causing visual disturbances under low illumination.<sup>2</sup>

The extraction of an intrastromal lenticule delineated by a femtosecond laser through a small incision (lenticule extraction) is a well-established technique for the correction of myopia and myopic astigmatism; the first laser platform to perform lenticule extraction has been the Zeiss SMILE (SMall Incision Lenticule Extraction).<sup>3</sup> Compared to laser in situ keratomileusis (LASIK), lenticule extraction provides a larger EOZ,<sup>4,5</sup> still smaller than the POZ by 16 to 22%.<sup>4,5-8</sup>

CLEAR® (Corneal Lenticule Extraction for Advanced Refractive correction), the application of the low-energy femtosecond laser Z8 (Ziemer Group, Port), is an emerging method to perform lenticule extraction, with the same principles and technique as SMILE but with a different lenticule geometry;<sup>9</sup> EOZ after CLEAR has not been measured nor compared with LASIK. We have therefore conducted a retrospective study with a 6-month follow-up to evaluate the EOZ after the Ziemer CLEAR procedure, using a post-LASIK sample as a control group.

## Materials and Methods

A retrospective, consecutive, comparative case series study was designed, including consecutive patients undergone uneventful lenticule extraction with the Ziemer CLEAR® between September and December 2022 in a single-institute series; the control group was composed by eyes undergone femtosecond LASIK with the same inclusion criteria. The Institutional Review Board provided approval on July 1, 2023. The research followed the tenets of the Declaration of Helsinki.

Pre-operative inclusion criteria were: i) myopia or compound myopic astigmatism with spherical equivalent (SE) -1 to -11 diopters (D), with a maximum astigmatism of 1D. High astigmatism was excluded to avoid an enlarging effect on EOZ;<sup>10</sup> ii) age: between 21 and 55 years; iii) general health status: absence of collagen vascular disease, no pregnancy; iv) ocular disease: no previous surgery; absence of scars or epithelial irregularities;

absence of macular or lens abnormality; no topical treatment for ocular hypertension; absence of dry eye symptoms, non-invasive tear film break-up time  $\geq 10$  seconds (MS-39, Costruzione Strumenti Oftalmici), lacrimal fluid osmolarity  $\leq 300$  mOsm/l (I-PEN, Imedpharma); v) corneal features on OCT and Placido topography (MS-39): central pachymetry  $\geq 500$   $\mu\text{m}$ ; regular posterior elevation, anterior and posterior tangential topography; no signs of ectasia; vi) corrected distance visual acuity (CDVA)  $\geq 20/40$  Snellen; vii) minimum follow-up: 6 months from treatment. Pre-operative assessment consisted of uncorrected distance visual acuity (UDVA), CDVA, manifest and cycloplegic refraction (by tropicamide eye drops), undilated and dilated slit-lamp evaluation, Placido corneal topography, OCT and Scheimpflug camera tomography, computer-assisted scotopic pupillography with identification of the Chang-Waring chord  $\mu\text{m}$ , defined as the distance from the pupil center (line of sight) to the light reflex (topographer axis),<sup>11</sup> tonometry, tear function evaluation.

Soft contact lens use was interrupted 1 month before examination and surgery; rigid contact lens use was interrupted 3 months before examination and surgery. All patients were informed about the surgical procedure and provided written consent.

### *Surgical technique for lenticule extraction*

Our technique for CLEAR has been published in detail.<sup>9</sup> Briefly, on the Ziemer LDV Z8 femtosecond laser, full manifest spherical and cylindrical corrections were planned. The optical zone was programmed to be the largest possible between 6 and 7 mm, depending on the amount of residual tissue resulting. The thickness of the cap (cornea anterior to the upper lenticule interface) in this series was 135  $\mu\text{m}$  in all eyes. In all cases, it was programmed to leave a stromal bed (tissue posterior to the lower lenticule interface) thick  $\geq 250$   $\mu\text{m}$  and a total residual uncut stroma (stromal cap + residual stromal bed)<sup>12</sup> thick  $\geq 320$   $\mu\text{m}$ . A single 2.5 mm-incision was programmed supero-temporally. The suction ring diameter was chosen according to white-to-white diameter measured by OCT: with diameters  $\geq 12$  mm, a 9.5 mm ring was used; with smaller diameters, a 9 mm ring. Femtosecond laser power and velocity were adjusted to obtain a uniform pattern of tiny, non-confluent plasma bubbles.

After topical anesthesia (2 drops of oxybuprocaine), the

patient was laid on the operating bed of an excimer laser (Teneo 317 M2, Bausch and Lomb), to use its operating microscope and slit lamp. After reviewing the preoperative image of the mu chord, the corneal vertex was confirmed by the first Purkinje reflex of the excimer fixation light. A drop of unpreserved 0.2% sodium hyaluronate was dripped on the cornea. The Ziemer Z8 handpiece was docked, the patient instructed to look into the red fixation light within the handpiece, suction activated, and centration accomplished on coaxially sighted light reflex.<sup>13</sup>

After laser lenticule delineation, the incision was scored and opened, and the lenticule separated with a Reinstein Lenticule Separator (Malosa MMSU1297S). Straight, fine-tip tying forceps (Malosa MMSU1414CS) were used to grasp the lenticule and extract it. The integrity of the distended lenticule was checked at the operating microscope, and the cap smoothed with radial movements of a partially wet surgical microsp sponge.

Topical post-operative treatment consisted of dexamethasone 0.1% and netilmicin 0.3% eyedrops 4 times daily for 5 days and then 3 times daily for 5 days, and unpreserved 0.2% sodium hyaluronate as lubricant as needed.

### *Surgical technique for femtosecond LASIK*

The corneal flap was created with a Ziemer LDV Z8 femtosecond laser. Flaps were programmed to a nominal thickness calculated by adding 40  $\mu\text{m}$  to the epithelial thickness as measured by OCT, always preserving a residual stromal bed  $\geq 300$   $\mu\text{m}$ , with a superior hinge and a 30° side-cut angle. The nominal flap diameter, determined by a different suction ring diameter, was 8.5 to 9.5 mm, depending on white-to-white diameter (as measured by OCT). Femtosecond laser power and velocity were adjusted to obtain a uniform pattern of tiny, non-confluent plasma bubbles. After topical anesthesia (2 drops of oxybuprocaine) and just before applanation, 2 drops of unpreserved 0.2% sodium hyaluronate were dripped on the cornea. After the completion of the femtosecond treatment, the flap was lifted with a single-use elevator (Malosa MMSU1171) and folded superiorly ('taco' fashion), and the stromal bed dried with a Merocel microsp sponge.

For the refractive treatment, a Technolas 317 Teneo M2 excimer laser was used (Bausch & Lomb). Full manifest refraction was used, aiming at emmetropia, with an optical zone comprised between 6.0 and 7.5 mm, in Planoscan mode; the ablation was centered on the coaxially sighted

corneal light reflex. Soon after ablation, the flap was repositioned and the interface irrigated for 2 seconds with balanced salt solution through a single-use 25 G cannula. The flap was then smoothed down with a wet microsp sponge in a radial fashion. A slit-lamp examination was performed 30 minutes after surgery.

Topical post-operative treatment consisted of dexamethasone 0.1% and netilmicin 0.3% eyedrops 4 times daily for 7 days, and unpreserved 0.2% sodium hyaluronate as lubricant as needed.

For both lenticule extraction and LASIK, standard follow-up visits were made at 1, 7, and 30 days; at 3 and 6 months. All visits after day 1 comprised slit lamp examination, manifest CDVA, UDVA, and tonometry. AS-OCT was performed at 3 and 6 months.

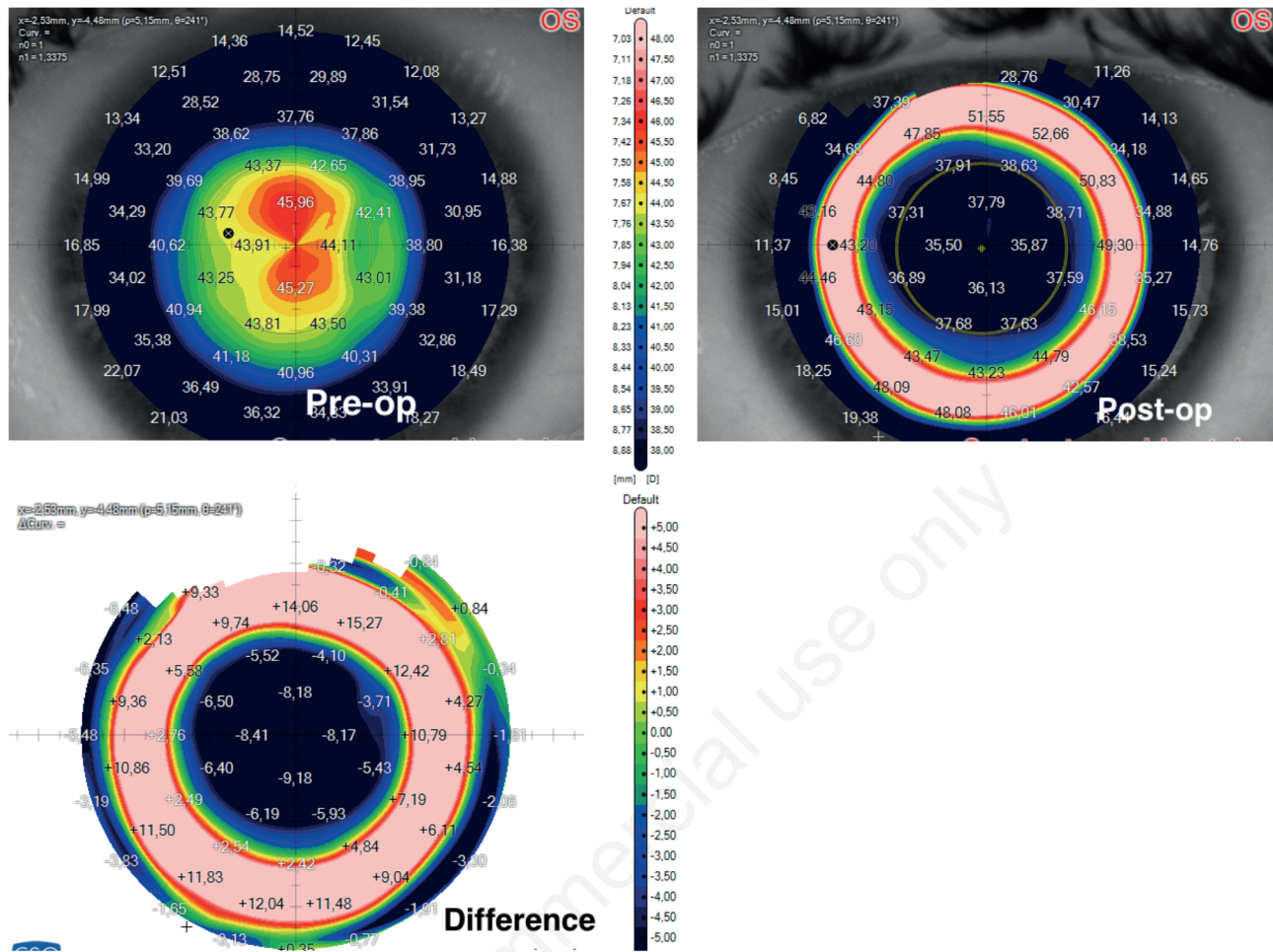
### *Data analysis*

As validated by previous articles,<sup>1,4-7</sup> the EOZ was measured on the difference map of pre-operative vs. post-operative tangential topography and defined as the area delineated by a 0 D change on the subtraction plot (Figure 1). The average EOZ was obtained by the mean of the long and short axes.<sup>7</sup>

Statistical analysis was performed with the SPS software, available online at [www.statisticsfordataanalysis.com](http://www.statisticsfordataanalysis.com) (accessed 12 July 2023). The mean  $\pm$  standard deviation was used to describe quantitative variables, and a  $p$  value less than .05 considered statistically significant. Student  $t$ -test for paired data and a 95% confidence interval (95%CI) were used to compare POZ and EOZ. Student  $t$ -test for unpaired data and a 95% confidence interval (95%CI) were used to compare data from lenticule extraction and LASIK. Pearson's  $r$  coefficient was used to verify the correlation between SE and percent reduction of EOZ, considering values from 0.31 to 0.50 as weak, values from 0.51 to 0.70 as moderate, and values  $>0.7$  as strong correlation.<sup>14</sup> In patients receiving bilateral treatment, the eye for the study was randomized.

### *Results*

A total of 80 eyes of 80 patients were finally included in the study, 40 for the lenticule extraction cases and 40 for the LASIK controls. Refractive results are presented in Table 1.



**Figure 1.** Corneal tangential topography before (top left) and 6 months after (top right) lenticule extraction for myopia (left eye, -10 -0,75 x 175° diopters) by lenticule extraction with the CLEAR application. Bottom: difference map where the effective optical zone (EOZ) is the area delimited by the light green circle indicating the 0.00 diopter change. With a programmed optical zone diameter of 6.2 mm, the EOZ resulted 5.1 mm.

**Table 1.** Refractive data of the case/control groups 6 months after laser vision correction; p values are calculated with two-tailed t-test for unpaired data.

| Parameter                        | Lenticule extraction | Femtosecond LASIK       |
|----------------------------------|----------------------|-------------------------|
| Pre-op CDVA (logMAR)             | 0.05±0.10            | 0.05±0.08 ( $p=1$ )     |
| Post-op UDVA (logMAR)            | 0.04±0.08            | 0.02±0.07 ( $p=0.47$ )  |
| % of eyes with UDVA $\geq 20/16$ | 40                   | 100                     |
| % of eyes with UDVA $\geq 20/20$ | 95                   | 95                      |
| Efficacy index                   | 1.02                 | 1.06                    |
| Post-op CDVA (logMAR)            | 0.03±0.09            | 0.00±0.04 ( $p=0.11$ )  |
| Eyes losing >1 line of CDVA      | 0                    | 0                       |
| Safety index                     | 1.05                 | 1.12                    |
| Post-op SE (diopters)            | -0.09±0.28           | -0.12±0.16 ( $p=0.56$ ) |
| % of eyes $\leq 0.50$ D of SE    | 95                   | 95                      |
| % of eyes $\leq 1$ D of SE       | 100                  | 100                     |

CDVA, corrected distance visual acuity; UDVA, uncorrected distance visual acuity; logMAR, logarithm of minimum angle of resolution; SE, spherical equivalent; Efficacy index, post-operative UDVA/pre-operative CDVA; Safety index, post-operative CDVA/pre-operative CDVA.



### Lenticule extraction

Females were 25 (63%). Mean age was 32.3 years, standard deviation  $\pm 10.7$ , range 21 to 55. Right eyes were 19 (48%). Pre-operative mean SE was  $-6.03 \pm 2.48$  D, range -2 to -10.5.

Mean POZ was  $6.43 \pm 0.27$  (range 6.0 to 6.8). Mean EOZ was  $5.55 \pm 0.45$  mm (range 4.8 to 6.4). The mean difference between POZ and EOZ was  $0.88 \pm 0.28$  mm, range 0.3 to 1.4 mm; two-tailed *t*-test for paired data: 18.51, with  $p=0.00$ . Mean reduction of EOZ compared to POZ was  $13.60\% \pm 4.75$  (range 4 to 22%).

The regression line relating preoperative SE and percent reduction of EOZ was  $y=1.21x+6.33$ ; a moderate positive correlation was shown by a  $r=0.63$ ;  $R^2$  was 0.40 (Figure 2).

### Femtosecond LASIK

Females were 21 (33%). Mean age was 34.1 years, standard deviation  $\pm 9.2$ , range 23 to 54. Right eyes were 21 (53%). Pre-operative mean SE was  $-5.89 \pm 2.14$  D, range -2.37 to -9.75.

Mean POZ was  $6.57 \pm 0.34$  (range 6.0 to 7.2). Mean EOZ

was  $5.16 \pm 0.53$  mm (range 4.7 to 6.6). The mean difference between POZ and EOZ was  $1.41 \pm 0.35$  mm, range 0.5 to 1.8 mm; two-tailed *t*-test for paired data: 7.48, with  $p=0.00$ . Mean reduction of EOZ compared to POZ was  $21.46\% \pm 5.20$  (range 8 to 28%).

### Lenticule extraction versus femtosecond LASIK

The mean difference between POZ of the 2 procedures was -0.14 mm; *t*-test for unpaired data: 2.04, with  $p=0.08$  (95%CI -0.28 to 0.00).

The mean difference between EOZ of the 2 procedures was 0.39 mm; *t*-test for unpaired data: 3.55, with  $p=0.0008$  (95%CI 0.17 to 0.61).

The mean difference between the reduction in optical zone (from POZ to EOZ) of the 2 procedures was -0.53 mm; *t*-test for unpaired data: 7.48, with  $p=0.00$  (95%CI -0.67 to -0.39).

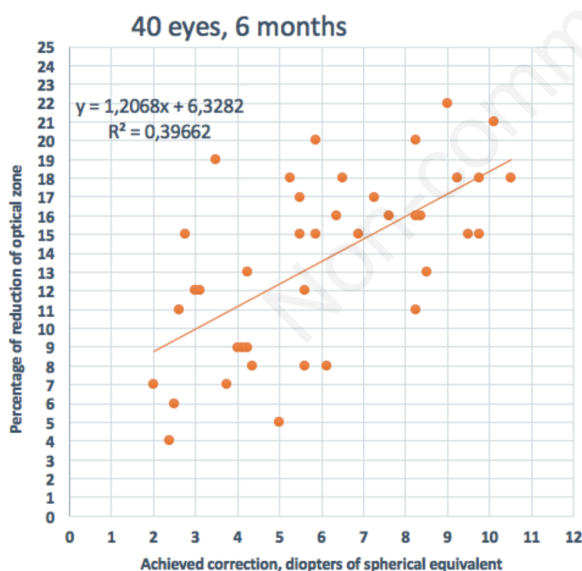
### Discussion

In the present study, the mean EOZ after lenticule extraction was smaller than the POZ by 0.88 mm (13.60%), whereas, after LASIK, the mean EOZ was smaller than the POZ by 1.41 mm (21.46%). These data are in agreement with previous studies conducted on lenticule extraction performed with a preexisting laser platform, in which the optical zone reduction was comprised between 16 and 22%, and in LASIK between 23 and 26%.<sup>4-8</sup>

In our study, the reduction in optical zone after lenticule extraction had a moderate relation with the achieved SE correction ( $r=0.63$ ); this in agreement with a previous study ( $r=0.45$ )<sup>8</sup> and in contrast with another, in which no correlation was found ( $r=0.15$ ).<sup>15</sup>

We found no significant difference in postoperative UDVA and CDVA between CLEAR and LASIK groups at 6 months. In addition, similar safety and efficacy index were observed.

The difference in EOZ between lenticule extraction and LASIK has been attributed to the reduced effect of excimer laser in the peripheral ablation,<sup>16</sup> to different post-inflammatory healing patterns,<sup>4</sup> and to the preservation of the anterior cornea in lenticule extraction, causing a different biomechanical response.<sup>5,17</sup> After noticing larger EOZ in SMILE compared to LASIK, Damgaard *et al.* hypothesized that the biomechanical response in the periph-



**Figure 2.** Correlation between achieved correction in diopters (spherical equivalent) and percent reduction of the effective optical zone compared to programmed optical zone after the correction of myopia by lenticule extraction with the CLEAR platform. The Pearson correlation coefficient  $r$  was 0.63.

eral cornea would be smaller after lenticule extraction than LASIK,<sup>5</sup> because the anterior collagen fibers remain intact in the former.<sup>18</sup> This would attenuate the peripheral relaxation toward the limbal base of the peripheral part of the collagen causing a central hyperopic shift<sup>19</sup> and therefore maintain larger EOZ.

Change in corneal asphericity is the main reason for the reduction of EOZ after excimer laser refractive surgery.<sup>20</sup> Similarly, in lenticule extraction surgery it has been shown that a more spheroidal postoperative shape of the cornea results in a smaller EOZ size.<sup>8</sup> To attenuate the reduction of the EOZ and to compensate for the spherical aberration induced after CLEAR treatment, the lenticule resection trajectory was designed to include a Q-factor customized aspheric femtosecond laser resection profile that respects the preoperative and postoperative asphericity of the cornea.<sup>21</sup>

The CLEAR application has a unique lenticule geometry, and this study was the first to assess its effect on EOZ, which compares favorably to LASIK and to existing lenticule extraction laser platforms.<sup>7,8</sup> In CLEAR, the POZ is grossly equivalent to the diameter of the lenticule,<sup>9</sup> which is determined by the extent of the posterior (refractive) cut. The lenticule is peripherally tapered, as the posterior cut meets the anterior cut: this feature may contribute to a larger EOZ, lacking an abrupt lenticule edge. Compared to LASIK, lenticule extraction leaves an almost intact anterior cornea in the cap, while reducing the stromal bed thickness; this aspect can affect corneal biomechanics<sup>22</sup> and must be taken into account in the choice of the procedure on the single patient.

This study has several limitations, including the retrospective design. The calculation of EOZ can be performed by several methods, which can lead to different results;<sup>1,6,8,15,23</sup> we chose the most used and reproducible method (difference map on tangential topography) in similar previous studies. We did not evaluate the subjective effect on vision of the EOZ, nor the changes in spherical aberration.

## Conclusions

In myopia with low astigmatism, the CLEAR application for lenticule extraction provided a limited reduction in EOZ, compared with existing platforms. A positive correlation exists between corrected SE and reduction in EOZ. These findings have a clinical relevance, since a

larger optical zone causes less spherical aberration and a better visual quality under low illumination; lenticule extraction may be therefore more appropriate in cases where LASIK cannot achieve an adequate optical zone.

**Contributions:** AL and SVF have contributed to the conception, drafting, final approval, and agreement to be accountable to all aspects of the work. GDB has contributed to the analysis of data, revising, final approval, and agreement to be accountable to all aspects of the work. CC has contributed to the conception, analysis of data, final approval, and agreement to be accountable to all aspects of the work.

**Conflict of interest:** the authors have no conflicts of interest to declare.

**Ethics approval:** the study has been granted an exemption from requiring ethics approval by the Institutional Review Board at Siena Eye Laser. Ethical approval is not required for this study in accordance with national guidelines.

**Informed consent:** all patients participating in this study signed a written informed consent form for participating in this study.

**Patient consent for publication:** written informed consent was obtained from a legally authorized representative(s) for anonymized patient information to be published in this article.

**Availability of data and materials:** all data generated or analyzed during the study are included in this article.

## References

1. Tabernero J, Klyce SD, Sarver EJ, Artal P. Functional optical zone of the cornea. *Invest Ophthalmol Vis Sci* 2007;48:1053-60.
2. Freedman KA, Brown SM, Mathews SM, Young RSL. Pupil size and the ablation zone in laser refractive surgery: considerations

- based on geometric optics. *J Cataract Refract Surg* 2003;29:1924-31.
3. Sekundo W, Kunert KS, Blum M. Small incision corneal refractive surgery using the small incision lenticule extraction (SMILE) procedure for the correction of myopia and myopic astigmatism: results of a 6 month prospective study. *Br J Ophthalmol* 2011;95:335-9.
4. Hou J, Wang Y, Lei Y, Zheng X. Comparison of effective optical zone after small-incision lenticule extraction and femtosecond laser-assisted laser in situ keratomileusis for myopia. *J Cataract Refract Surg* 2018;44:1179-85.
5. Damgaard IB, Ang M, Mahmoud AM, et al. Functional optical zone and centration following SMILE and LASIK: a prospective, randomized, contralateral eye study. *J Refract Surg* 2019;35:230-7.
6. Sun L, Lin H-N, Jhanji V, et al. Changes in effective optical zone after small-incision lenticule extraction in high myopia. *Int Ophthalmol* 2022;42:3703-11.
7. Liu S, Zhang X, Niu L, et al. Comparison of the functional optical zone in eyes with high myopia with high astigmatism after SMILE and FS-LASIK. *J Refract Surg* 2022;38:595-601.
8. Song YW, Cui MF, Feng Y, et al. Comparative study of functional optical zone: small incision lenticule extraction versus femtosecond laser assisted excimer laser keratomileusis. *Int J Ophthalmol* 2023;16:238-44.
9. Leccisotti A, Fields SV, De Bartolo G. Refractive corneal lenticule extraction with the CLEAR femtosecond laser application. *Cornea* 2023;42:1247-56.
10. Ding X, Fu D, Wang L, et al. Functional optical zone and visual quality after small-incision lenticule extraction for high myopic astigmatism. *Ophthalmol Ther* 2021;10:273-88.
11. Chang DH, Waring GO IV. The subject-fixated coaxially sighted corneal light reflex: a clinical marker for centration of refractive treatments and devices. *Am J Ophthalmol* 2014;158:863-74.
12. Reinstein DZ, Archer TJ, Randleman JB. Mathematical model to compare the relative tensile strength of the cornea after PRK, LASIK, and small incision lenticule extraction. *J Refract Surg* 2013;29:454-60.
13. Reinstein DZ, Gobbe M, Archer TJ. Coaxially sighted corneal light reflex versus entrance pupil center centration of moderate to high hyperopic corneal ablations in eyes with small and large angle kappa. *J Refract Surg* 2013;29:518-25.
14. Miot HA. Correlation analysis in clinical and experimental studies. *J Vasc Bras* 2018;17:275-9.
15. Huang Y, Ding X, Han T, et al. Effective optical zone following small incision lenticule extraction for myopia calculated with two novel methods. *J Refract Surg* 2022;38:414-21.
16. He S, Luo Y, Chen P, et al. Prospective, randomized, contralateral eye comparison of functional optical zone, and visual quality after SMILE and FS-LASIK for high myopia. *Transl Vis Sci Technol* 2022;11:13.
17. Wei PH, Wang Y, Li H, et al. Effect of optical zone diameter on corneal biomechanical properties after small incision lenticule extraction. [*Zhonghua yan ke za zhi*] *Chinese J Ophthalmol* 2017;53:182-7.
18. Roy AS, Dupps WJ Jr, Roberts CJ. Comparison of biomechanical effects of small-incision lenticule extraction and laser in situ keratomileusis: finite-element analysis. *J Cataract Refract Surg* 2014;40:971-80.
19. Dupps WJ Jr, Roberts C. Effect of acute biomechanical changes on corneal curvature after photokeratectomy. *J Refract Surg* 2001;17:658-69.
20. Ying J, Cai J, Zhu L, Zha Y. Comprehensive evaluation of anterior corneal change in asphericity calculated by the tangential radius of curvature after LASIK. *J Ophthalmol* 2017;3874371.
21. Koller T, Iseli HP, Hafezi F, et al. Q-factor customized ablation profile for the correction of myopic astigmatism. *J Cataract Refract Surg* 2006;32:584-9.
22. Hashemi H, Roberts CJ, Elsheikh A, et al. Corneal biomechanics after SMILE, femtosecond-assisted LASIK, and photorefractive keratectomy: A matched comparison study. *Transl Vis Sci Technol* 2023;12:12.
23. Li H, Peng Y, Chen M, et al. Six modes of corneal topography for evaluation of ablation zones after small-incision lenticule extraction and femtosecond laser-assisted in situ keratomileusis. *Graefes Arch Clin Exp Ophthalmol* 2020;258:1555-63.