

A comparative study of photobiomodulation enhancing hemostasis in older patients at risk of extraction socket bleeding

Suwat Tanya,^{1,2} Piyachat Patcharanuchat,^{2,3} Sajee Sattayut^{2,4}

¹Graduate School, Faculty of Dentistry, Khon Kaen University; ²Lasers in Dentistry Research Group, Khon Kaen University; ³Department of Preventive Dentistry, Faculty of Dentistry, Khon Kaen University; ⁴Department of Oral and Maxillofacial Surgery, Faculty of Dentistry, Khon Kaen University, Thailand

ABSTRACT

Laser therapy effectively reduces the risk of excessive bleeding, a critical condition in rural healthcare units due to limited hemostatic tools and specialist availability. This research aimed to compare the clinical outcomes of utilizing lasers to enhance socket hemostasis in Thailand's primary, secondary, and tertiary-level healthcare units. This prospective observational study involved a total of 27 patients, aged 50 and older, who were at risk of extraction socket bleeding due to medications or gingival inflammation. Each study unit provided routine dental treatments along with supplemental laser therapy, as chosen by the operators. A single researcher assessed the related clinical outcomes. Primary and secondary-level healthcare units utilized an 810 nm diode laser; in contrast, a tertiary-level healthcare unit employed a 635 nm and 980 nm diode laser. Soft-assisted tissue loosening was conducted using 810 nm or 980 nm diode lasers, with a power of 2.5 to 3 W delivered via a 320-micron optical fiber. To initiate blood clot formation, a 635 nm at 0.2 W, 5.08 J/cm² via 8-mm diameter laser probe, or 810 nm at 0.8 W, 5.93 J/cm² via 6-mm diameter biomodulation probe was applied for 10 s per session.

Secondary and tertiary-level healthcare units often combined laser-assisted soft tissue loosening and photobiomodulation, whereas the primary-level healthcare unit generally opted for utilizing photobiomodulation alone ($p < 0.001$). Laser therapies employed in this study achieved socket hemostasis in 72 out of 86 sockets, with 55 achieving hemostasis within 5 min. The operators confirmed the clinical efficacy in reducing hemostasis duration across all study units ($p = 0.702$), without experiencing post-extraction bleeding or clinical complications.

Our findings indicate that a combination of laser-assisted soft tissue loosening and photobiomodulation to induce blood clot formation is a safe and effective local measure for enhancing socket hemostasis.

Key words: photocoagulation; photobiomodulation; bleeding; healthcare unit; gerontology.

Corresponding author:

Professor Sajee Sattayut, Department of Oral and Maxillofacial Surgery, Faculty of Dentistry, Khon Kaen University, Khon Kaen 40002, Thailand.
Telephone: +66935466178.
E-mail: sajee@kku.ac.th

Received: 30 September 2024.

Accepted: 23 February 2025.

Laser Therapy

©Copyright: the Author(s), 2025

Licensee PAGEPress, Italy

Laser Therapy 2025; 32:411

doi:10.4081/ltrj.2025.411

Introduction

In routine dental extractions, uncontrolled bleeding may occur in patients with bleeding disorders, multiple systemic diseases, or specific local factors like severe gingival inflammation.¹⁻³ A retrospective study by Shao *et al.* in 2024 indicated that individuals aged over 60 years old were at elevated risk for post-extraction bleeding (PEB).⁴ This risk was compounded in those undergoing oral antithrombotic therapy, which includes anticoagulants^{5,6} or dual antiplatelet therapy (DAPT).⁷ Both primary and secondary-level healthcare units in Thailand reported uncontrolled bleeding in routine dental practice, especially in older patients on medications that induced bleeding and those with severe gingival inflammation.⁸ A systematic review and meta-analysis by Mahardawi *et al.* in 2023 demonstrated that the use of additional hemostasis measures significantly reduced the incidence of PEB, particularly in patients undergoing oral antithrombotic therapy, by aiding blood clot stability in the bleeding socket.⁹ However, the application of hemostatic sponges was associated with an increased risk of socket bleeding due to expansion effects compared to pressure hemostasis techniques.⁹ Despite being generally resorbable, some hemostasis agents could occasionally trigger foreign body reactions or allergic responses,¹⁰ although such instances were rare. Laser therapy has recently emerged as an innovative technique providing enhanced socket hemostasis and introducing new perspectives for managing bleeding in dental practices. Since 2011, photobiomodulation, a new laser technique that initiates blood clotting using light-emitting diode (LED) irradiation, has proven effective in accelerating extraction socket hemostasis both in healthy individuals¹¹⁻¹³ and those on warfarin,¹⁴ surpassing conventional pressure hemostasis. However, LED use has some drawbacks, such as uncontrollable heat generation, fixed power levels due to device design, and emission across a broad spectrum of wavelengths. To tackle these limitations, non-thermal laser therapy employing photobiomodulation (PBM) was introduced to enhance blood clot formation in bleeding extraction sockets.^{8,15-19} Laboratory studies have examined the effects of red light (632.8 to 670 nm) on red blood cell aggregation,²⁰⁻²² and clinical studies have demonstrated the effectiveness of PBM using infrared light (808 to 980 nm) to initiate blood clot formation in bleeding sockets.^{8,15-19} The crucial randomized controlled trial (RCT) executed by Kelkar *et al.* in 2023 also corroborated the effectiveness of a 980 nm diode laser in signif-

icantly accelerating socket hemostasis after tooth extraction in hemophiliacs.¹⁷ Despite these advantages, no studies have examined the techniques and clinical efficacy of laser therapy for enhancing blood clot formation after tooth extraction in older patients across various healthcare unit levels: primary, secondary, and tertiary. This prospective observational study aimed to explore laser therapy techniques used for improving socket hemostasis and to compare their related clinical outcomes across three different healthcare unit levels in Thailand.

Materials and Methods

Study design and study locations

A comparative study was carried out across three distinct healthcare unit levels, all part of the Lasers in Dentistry Research Group (LDRG) network at Khon Kaen University, Thailand. The study units included: i) a primary-level healthcare unit (Dental Clinic, Bua Ngoen sub-district health promoting hospital, Nam Phong District, Khon Kaen Province, Thailand); ii) a secondary-level healthcare unit (Dental Clinic, Borabue Hospital, Borabue District, Mahasarakham Province, Thailand); and iii) a tertiary-level healthcare unit (Orofacial Laserology Clinic, Department of Oral and Maxillofacial surgery, Faculty of Dentistry, Khon Kaen University, Thailand), which served as the original, or referent, group. All operators at these units were qualified in laser safety and application. The study spanned from October 2023 to August 2024, following the approval of the study protocols by the Khon Kaen University Ethics Committee for Human Research (HE672088).

Study size estimation

A survey of studies conducted between July 2021 and March 2022 analyzed the use of laser therapy in primary and secondary healthcare units. In each study unit, five older patients were included.²³ Therefore, the estimated sample size for this study was set at a minimum of five older patients per unit.

Participant recruitment

Participants in this study were either regular or referred

patients seeking routine dental treatment. Comprehensive dental treatment planning and procedures were administered by operators at each study unit. The initial eligibility screening was conducted by the operator. Participants were purposefully invited to participate in the study by a single researcher (ST) who was not involved in the patient's treatment. Regarding patient rights, participants were informed that they could freely decline to participate in the study without any consequences. Regardless of their decision, they were assured that they would still receive routine dental treatment, including laser therapy. The inclusion criteria were as follows: patients had to be at least 50 years old, designated as American Society of Anesthesiologists Physical Status (ASA-PS) I to IV, literate, and in need of routine single or multiple tooth extractions. Eligible patients also had tendencies for socket bleeding due to oral antithrombotic therapy (single or dual antiplatelet therapy or anticoagulants) or local gingival inflammation. The patient adhered to laser safety measures, including the mandatory use of appropriate eye protection during laser operations. These criteria were applied consistently across all participating units. The exclusion criteria were patients with local anesthesia allergies, those unwilling to participate, individuals with hereditary bleeding disorders, and those who had undergone organ transplantation. Withdrawal criteria included cases where tooth extraction required dentoalveolar surgery. For participants with severe systemic health conditions or those undergoing oral antithrombotic therapy, a consultation with a physician was conducted before dental treatment.

Dental extraction procedure

Routine tooth extractions were conducted using a standardized atraumatic technique²³ by experienced operators in each study unit. Local anesthesia was administered with 2% mepivacaine hydrochloride (20 mg/mL) and adrenaline (1:100,000) (Scandonest 2% Special, Septodont, France, B32091AC, imported and distributed by Accord Corporation Limited, Thailand). An inferior alveolar and lingual nerve block were used for mandibular teeth, with additional buccal infiltration as needed, resulting in 1.5 to 1.8 mL of local anesthesia. A suprapariosteal injection and palatal infiltration were used for maxillary teeth, amounting to around 0.6 to 0.8 mL per procedure. If required, the socket was gently curetted after tooth extraction.

Laser procedures for enhancing socket hemostasis

The procedures included laser-assisted soft tissue loosening before tooth extraction and photobiomodulation therapy to initiate blood clot formation in the extraction socket. Regarding laser machine availability, primary and secondary healthcare units had access to an 810 nm diode laser, while a dual-wavelength diode laser (653 nm and 980 nm) was available at tertiary-level healthcare units. For patients at risk of a bleeding tendency prior to tooth extraction, laser therapy for sulcular fiber separation was recommended (Figures 1A and 2A). This technique, known as "laser-assisted soft tissue loosening", aims to ablate sulcular fibers and seal gingival blood vessels. It involves inserting a fiber optic tip into the periodontal sulcus and moving it up and down until a whitish coagulative zone appears. The tip was inserted 2 to 3 mm into the sulcus, avoiding the periosteum. The laser parameters used in this study included an 810 nm diode laser (PICASSO™ LITE, AMD Lasers, Indiana) and a 980 nm diode laser (SmartM, Lasotronix, Piaseczno, Poland) at a power of 2.5 to 3 W in continuous wave mode. The use of this technique was optional and was based on the operator's decision.

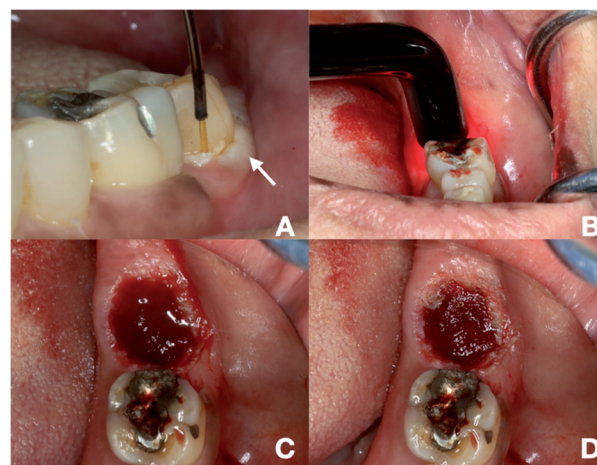


Figure 1. A combination of laser-assisted soft tissue loosening and PBM to initiate blood clot formation used in a 73-year-old Thai female taking aspirin with clopidogrel. A) Laser-assisted soft tissue loosening using a 980 nm diode laser with fiber optic (white arrow indicates the whitish coagulative zone surrounding gingival sulcus); B) PBM to initiate blood clot formation using a 635 nm diode laser with an 8 mm-diameter laser probe; C) initial clot formation within 5 min following laser hemostasis; D) complete clot formation within 20 min following laser with pressure hemostasis.

After tooth extraction, bleeding sockets were treated with laser therapy for hemostasis (Figures 1B and 2B). A technique known as “PBM for initiating blood clot” was employed with specific laser parameters: an 810 nm diode laser with a power output of 0.8 W that delivers an energy density of 5.93 J/cm² in continuous wave mode, using a 6 mm diameter biomodulation laser probe, or a 635 nm diode laser (SmartM, Lasotronix, Piaseczno, Poland) with a power output of 0.2 W in continuous wave mode, delivering an energy density of 5.08 J/cm² using an 8 mm diameter laser probe. The use of the laser comprised irradiating the bleeding socket for 10 s per session, with an initial four sessions recommended. If the bleeding persisted, more PBM sessions were carried out. Other hemostasis techniques were implemented as needed. The total observation period lasted 30 min and assessments were carried out every 5 min.

Post-extraction instruction and evaluation

Analgesics were prescribed to be taken as needed every 6 h. For 2 days after the extraction, patients adhered to a soft diet and were instructed to return to the study units if any re-bleeding occurred. Follow-up evaluations were tentatively scheduled for 2 to 4 weeks post-extraction. If patients could not return for a visit, a phone interview was conducted by the operator.

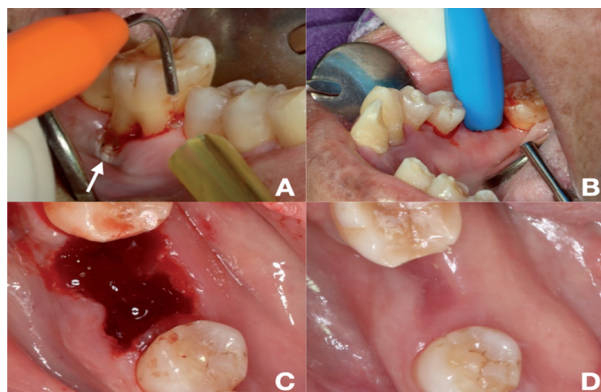


Figure 2. A combination of laser-assisted soft tissue loosening and PBM to initiate blood clot formation used in a 58-year-old Thai female with diabetes. A) Laser-assisted soft tissue loosening using an 810 nm diode laser with fiber optic (white arrow indicates the whitish coagulative zone); B) PBM to induce blood clot formation using an 810 nm diode laser with a biomodulation probe; C) complete clot formation within 10 min following laser hemostasis; D) 2-week follow-up indicating complete mucosal coverage.

Assessments of socket hemostasis and clinical efficacy

Hemostasis of the socket was clinically evaluated by both the operator and the researcher (ST) within 10 s. The criteria included: i) active bleeding, characterized by continuous blood flow; ii) sluggish oozing, defined by blood movement without overflow; and iii) clot formation, identified by a gel-like blood clot. Complete socket hemostasis was confirmed through an agreement between the operator and the researcher (ST).

Before the evaluation of clinical efficacy, the operator performed clinical data verification. The criteria were as follows: i) positive: effective or expedited hemostasis achieved with laser therapy or in combination with other measures; ii) neutral: hemostasis achieved at a rate comparable to the norm; iii) negative: hemostasis achieved at a slower rate than expected; iv) partial effectiveness: reactionary bleeding occurring 2 to 3 h post-extraction; v) non-effectiveness: persistent bleeding beyond 12 h, mandating return visits, hospitalization, or blood transfusion.

Variable and measurement

The primary outcome of this study was the technique of laser therapy utilized for socket hemostasis. Other related clinical outcomes included the duration of hemostasis, the efficacy of laser therapies, the incidence of PEB, and any adverse effects.

Bias

Before treatment visits, participants underwent initial screening and dental treatment planning carried out by healthcare providers or operators in each study unit. Appointments for tooth extractions were then scheduled. During the treatment visit, participants were informed about laser therapy and invited to participate by the researcher (ST), who was not directly involved in the dental procedures.

Statistical analysis

The data recorded in this study were processed and analyzed using the SPSS program (version 29.0.2.0 Armonk, NY: IBM Corp.). All analyses in this study were two-sided and were conducted at a significance level of 0.05. The normality of participants' ages and irradiation sessions was

explored using Shapiro-Wilk tests. Continuous variables were expressed as averages with their 95% confidence intervals (95% CI), while categorical variables were presented as frequencies. Comparisons of participants' proportions by demographic data across three study units were performed using the chi-square test. In the event of low expected frequency in the contingency table, Fisher's exact test was performed instead. To determine differences in the proportion of extraction sockets by clinical data among the three different study units, either the chi-square test or Fisher's exact test was performed, depending on the expected frequencies in the contingency table.

Results

All patients in this study received routine dental treatments conducted by dentists at each study site. For patients at risk of bleeding after tooth extraction, laser therapies were used to expedite socket hemostasis. The requirement for laser therapies was determined by the operator, and they were used only after obtaining informed consent from the patient.

Patient characteristic

Between October 2023 and August 2024, a total of 27 patients were included across all three study units, with

more than half undergoing multiple tooth extractions. Of these, 16 were female and 11 were male. The average age, with a 95% confidence interval, was 64.78 (61.03 to 68.52). Twelve patients were receiving oral antithrombotic therapy. The laser parameters used in this study are detailed in Table 1. The demographic characteristics of the patients, as presented in Table 2, showed no statistically significant differences across primary, secondary, and tertiary-level healthcare units in terms of gender ($p=0.540$), age ($p=0.339$), and tooth removal procedures ($p=0.885$). This underscores the demographic likeness of participants across the three study units. The proportions of patients classified as ASA-PS Class III and IV, as well as those with cardiovascular diseases, were significantly more likely to receive dental treatments at a tertiary-level healthcare unit ($p=0.001$ and $p=0.022$, respectively). Additionally, there was no significant difference in the proportion of patients classified by ASA-PS between primary and secondary-level healthcare units ($p=0.620$).

Number of extraction sockets in three study units and general characteristics

The total number of extraction sockets, as shown in Table 3, was 86 sockets across 27 participants. In primary and secondary-level healthcare units, periodontitis was the main reason for tooth extraction. However, tertiary-level

Table 1. Laser parameters used in this study.

Parameter (units)	PBM for initiating blood clot		Laser-assisted soft tissue loosening	
Wavelength (nm)	635	810±10	810±10	980
Laser type	diode, semiconductor	gallium-aluminum-arsenide (GaAlAs), diode laser	gallium-aluminum-arsenide (GaAlAs), diode laser	diode, semiconductor
Average power (mW)	0.2	0.8	2.5	3
Energy density (J/cm ²)	5.08	5.93	-	-
Probe diameter (mm)	8	6	-	-
Fiber diameter (micron)	-	-	320	320
Operating mode	continuous wave			
Application technique	contact mode			
Application mode	stationary, perpendicular to the extraction socket		moving up and down into the periodontal sulcus	
Irradiation time (s)	10 s per session		-	-
Laser off duration (s)	5 s		-	-
Model of device	SmartM, Lasotronix	PICASSO™ LITE	PICASSO™ LITE	SmartM, Lasotronix
Manufacturer	Piaseczno, Poland	AMD Lasers, Indiana	AMD Lasers, Indiana	Piaseczno, Poland

Table 2. Demographic data of the patients across three study units.

Demographic data	Primary-level healthcare unit (n=9)	Secondary-level healthcare unit (n=9)	Tertiary-level healthcare unit (n=9)	P-value
Gender (n=27)				
Male (n=11)	4	2	5	0.540 ^a
Female (n=16)	5	7	4	
Age with 95% CI	65.33(58.69 to 71.98)	64.78 (61.03 to 68.52) 59.22(54.47 to 63.97)	69.78(61.53 to 78.03)	0.339 ^b
Range (years)	53 to 82	50 to 68	52 to 88	
ASA physical status				
ASA-PS II (n=13)	5	7	1	0.010 ^a
ASA-PS III, IV (n=14)	4	2	8	
Patient health conditions				
Cardiovascular diseases (n=12)	4	1	7	0.022 ^a
Other systemic diseases (n=15)	5	8	2	
Oral antithrombotic therapy (n=12)				
SAPT (n=5)	4	0	1	-
DAPT (n=3)	0	0	3	
Warfarin (n=4)	0	1	3	
Procedures for tooth removal				
Single (n=12)	4	5	3	0.885 ^a
Multiple (n=15)	5	4	6	

n, number of subjects; *CI*, confidence interval; *ASA-PS*, American Society of Anesthesiologists Physical Status; *SAPT*, single antiplatelet therapy (aspirin); *DAPT*, dual antiplatelet therapy; ^aFisher's exact test; ^bShapiro-Wilk test.

Table 3. Number of extraction sockets across three study units and general characteristics.

General characteristics	Primary-level healthcare unit (32)	Secondary-level healthcare unit (22)	Tertiary-level healthcare unit (32)	P-value
(Number of extraction sockets)	86 sockets			
ASA physical status				
ASA-PS II (n=13)	22	11	3	<0.001 ^a
ASA-PS III, IV (n=14)	10	11	29	
Patient health conditions				
Cardiovascular diseases (n=12)	10	5	16	0.105 ^b
Other systemic diseases (n=15)	22	17	16	
Oral antithrombotic therapy (29)				
SAPT (n=5)	10	0	2	-
DAPT (n=3)	0	0	7	
Warfarin (n=4)	0	5	5	
Extraction socket location				
Anterior tooth (32)	13	7	12	0.815 ^b
Posterior tooth (54)	19	15	20	
Tooth diagnosis				
Periodontitis (53)	26	16	11	<0.001 ^b
Pulp necrosis or pulpitis (33)	6	6	21	
Periodontal treatment status (53)				
Controlled periodontal disease (30)	18	1	11	<0.001 ^a
Untreated periodontal disease (23)	8	15	0	
Risk of bleeding tendency				
Antithrombotic drugs (29)	10	5	14	0.260 ^b
Gingival inflammation (57)	22	17	18	

ASA-PS, American Society of Anesthesiologists-Physical Status; *n*, number of subjects; *SAPT*, single antiplatelet therapy (aspirin); *DAPT*, dual antiplatelet therapy; *PBM*, photobiomodulation; *HILT*, high-intensity laser therapy; ^aFisher's exact test; ^bchi-square test.

healthcare units primarily performed extractions due to pulp necrosis or pulpitis ($p < 0.001$). Patients' periodontal treatment status differed significantly between the three study units ($p < 0.001$). Most patients at the secondary-level healthcare unit had not completed periodontal treatment before extraction, whereas those in the primary-level healthcare unit typically received periodontal treatment before extraction.

Laser therapies used for enhancing socket hemostasis

As highlighted in Table 4, the use of PBM to initiate blood clot formation was significantly prevalent in primary-level healthcare units ($p < 0.001$). In contrast, secondary and tertiary-level healthcare units favored a different approach. The preferred laser technique in these units involved a combination of laser-assisted soft tissue loosening and PBM for initiating blood clotting.

Out of 86 bleeding sockets, 72 significantly achieved socket hemostasis by using laser therapy techniques alone ($p < 0.001$). The remaining 14 bleeding sockets from six participants required a combination of laser therapies and other hemostasis measures. Specifically, 12 sockets were managed with suturing, one socket received pressure hemostasis, and only one socket was treated with both surgical packing and suturing.

Time required for extraction socket hemostasis

During a 30-min clinical observation period, 55 bleeding extraction sockets achieved hemostasis within 5 min following laser therapies to enhance hemostasis (Figure 3). Complete clot formation was observed in sixteen, seven, and four sockets at 10, 15, and 20 min, respectively. The

remaining four sockets achieved hemostasis by the end of the 30-min observation period.

According to Table 5, over half of the bleeding sockets in secondary-level healthcare units required between 5 and 30 min to achieve socket hemostasis. However, the majority of bleeding sockets in both primary and tertiary-level healthcare units were controlled within 5 min ($p = 0.033$). Further comparison of the hemostasis duration between primary and tertiary-level healthcare units revealed no significant difference in the proportion of bleeding sockets controlled within 5 min ($p = 1.000$). Given the non-normal distribution of irradiation sessions, determined by the Shapiro-Wilk test ($p < 0.01$), the median was reported. The median number of irradiation sessions for

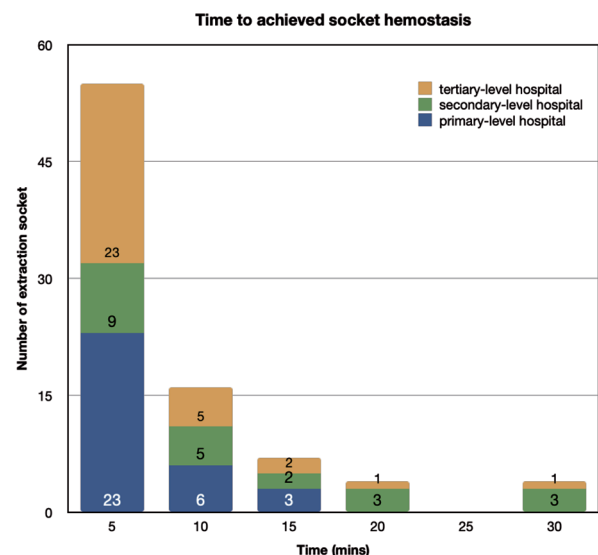


Figure 3. Number of sockets achieving hemostasis by times.

Table 4. Laser therapies used for enhancing extraction socket hemostasis.

Hemostasis techniques (Number of extraction sockets)	Primary-level healthcare unit (32)	Secondary-level healthcare unit (22)	Tertiary-level healthcare unit (32)	P-value
Laser therapy techniques				
PBM for initiating blood clot (25)	23 (n=9)	2 (n=2)	0	<0.001 ^a
Combination of laser-assisted soft tissue loosening and PBM for initiating blood clot (61)	9 (n=2)	20 (n=7)	32 (n=9)	
Local hemostasis techniques				
Laser therapies (72)	26 (n=8)	16 (n=8)	30 (n=7)	0.108 ^a
Laser therapies with other hemostasis measures (14)	6 (n=3)	6 (n=1)	2 (n=2)	

PBM, photobiomodulation; ^aFisher's exact test.

Table 5. Number of extraction sockets by related clinical outcomes.

Clinical outcomes (Number of extraction sockets)	Primary-level healthcare unit (32)	Secondary-level healthcare unit (22)	Tertiary-level healthcare unit (32)	P-value
Hemostasis duration				
Within 5 min (55)	23	9	23	0.033 ^b
Between 5 to 30 min (31)	9	13	9	
Effectiveness of laser therapy for initiating blood clot formation				
Positive hemostasis achieved (84)	32	21	31	0.702 ^a
Neutral hemostasis achieved (2)	0	1	1	
Negative hemostasis achieved (0)	0	0	0	
Partially effectiveness (0)	0	0	0	
Non-effectiveness (0)	0	0	0	
Post-extraction bleeding	0	0	0	-

^aFisher's exact test; ^bchi-square test.

sockets achieving hemostasis within 5 min was 4, ranging between 2 to 6 sessions, while sockets requiring between 5 to 30 min had a median of 8 sessions, with a range from 4 to 16 sessions.

Based on clinical assessments informed by the experiences of operators, laser therapies that enhance blood clot formation have been found to reduce the duration of hemostasis in all study units (p=0.702).

Discussion

The study revealed a preference for the combination of laser-assisted soft tissue loosening and PBM for initiating blood clot formation, particularly in secondary and tertiary-level healthcare units. In 2023, Cheng *et al.* emphasized that most PEB generally resulted from soft tissue trauma instead of bleeding from bone.³ The results demonstrated that the use of the 810 nm or 980 nm diode lasers effectively reduced soft tissue bleeding via a photocoagulation reaction. Morkmued *et al.* proposed that pre-extraction laser-assisted soft tissue loosening significantly enhanced socket hemostasis in patients with liver transplantation and factor VIII deficiency by instantaneously coagulating the soft tissue.²⁴ Within primary-level healthcare units, PBM was most commonly utilized to expedite blood clot formation. In addition, a 2023 RCT by Kelkar *et al.* first documented the clinical efficacy of PBM for initiating blood clotting in hemophilia patients.¹⁷ Today, it is generally acknowledged that the mechanism of PBM involves local nitric oxide (NO) activation.^{25,26} In 2022, Wajih *et al.* determined that the clotting effects induced by PBM were associated with

the level of NO on the surface of red blood cells (RBCs).²⁷ They found that a minimal quantity of NO generated on the RBC surface triggered platelet activation. Conversely, an increased NO amount resulted in platelet inhibition. Also, it was found that PBM-irradiating RBCs enhanced the RBCs' resistance to osmotic stress and hemolysis.²⁸ Furthermore, red light irradiation (632.7 nm) reactivated heme-containing enzymes in bovine RBCs.²⁹

Based on the findings, all three study units exhibited similar clinical outcomes, signifying that the laser therapies used in this study effectively reduced the time necessary for socket hemostasis without inducing clinical complications. Roughly two-thirds of all bleeding sockets achieved hemostasis within 5 min, which was markedly less than the suggested time of 30 to 60 min for pressure hemostasis application.²³ Furthermore, out of 86 bleeding sockets, 72 were controlled solely using laser therapies. The laser therapies utilized in this study received widespread approval from operators across all study units.

In addition to medication-induced bleeding, local gingival inflammation also increases the risk of bleeding after tooth extraction. The results showed that over 50% of patients in a secondary-level healthcare unit had a higher risk of bleeding due to severe gingival inflammation caused by untreated periodontal disease.³ Conversely, patients in tertiary-level healthcare units, classified as ASA-PS III and IV, were at risk of bleeding due to oral antithrombotic therapy used to manage cardiovascular disease. Cheng *et al.* (2023) reported that inflamed gingivae delayed hemostasis and the healing process, particularly in cases of untreated periodontal dis-

eases. This finding is consistent with our results, where a longer hemostasis duration was predominantly observed in patients at secondary-level healthcare units due to active periodontal diseases. While periodontitis was the primary reason for tooth extraction in the primary-level healthcare unit, most bleeding sockets were still controlled within 5 min using PBM alone to facilitate blood clot formation. Remarkably, the patients' periodontal status was well-controlled due to previously received periodontal treatment before tooth extraction. Studies by Kelkar *et al.*,¹⁷ Klangthong *et al.*,¹⁸ Malakam *et al.*,¹⁵ Hamzah *et al.*,¹⁶ and Sattayut *et al.*⁸ provided clinical evidence that utilizing PBM to initiate blood clot formation effectively shortened the hemostasis duration in both healthy individuals and patients with systemic health conditions.

The present study found no reports of PEB or other clinical complications from any of the study units. Patients experienced minimal pain at the extraction wound site and required less analgesic use. All operators observed accelerated mucosal healing upon the application of laser therapy techniques, even in cases of severe gingival inflammation.

It is essential to emphasize that the included participants did not require a systemic approach for hemostasis. All bleeding sockets were managed using local hemostasis measures. If patients require a systemic approach to hemostasis, it is worth further exploring the efficacy of laser therapy on extraction socket hemostasis.

Conclusions

A combination of laser-assisted soft tissue loosening through a photocoagulation reaction, along with PBM for initiating blood clot formation, was the recommended technique for enhancing socket hemostasis in older patients requiring tooth extraction. This laser therapy proved to be an effective and safe local hemostasis measure, shortening the duration of hemostasis, minimizing PEB, and preventing clinical complications across three different levels of healthcare units in Thailand.

Conflict of interest

The authors declare no potential conflict of interest.

Contributions

ST, conceptualization, methodology, validation, formal analysis, investigation, resources, data curation, writing—original draft preparation, visualization, project administration; PP, conceptualization, methodology, validation, data curation, writing – review and editing, visualization, supervision; SS, conceptualization, methodology, validation, formal analysis, investigation, resources, data curation, writing – review and editing, visualization, supervision, project administration, funding acquisition. All the authors have read and approved the final version of the manuscript and agreed to be accountable for all aspects of the work.

Ethics approval and consent to participate

The Khon Kaen University Ethics Committee for Human Research approved the study protocols based on the Declaration of Helsinki and the ICH good clinical practices guideline (No. HE672088). Informed consent was obtained from the patients included in this study.

Availability of data and materials

Data are available upon request from the corresponding author, in accordance with the regulations of the Khon Kaen University Ethics Committee for Human Research and with the consent of the study participants.

Funding

This study was supported by the Fundamental Fund (2024), which Khon Kaen University received from the National Science Research and Innovation Fund (NFRF) and the Lasers in Dentistry Research Group, Khon Kaen, Thailand.

Acknowledgments

The authors thank Ms. Sasitorn Phaosup, Public Health Officer at Bua Ngoen sub-district Health Promoting Hospital, Khon Kaen, Thailand; Ms. Kingtong Moon-

manee, Dentist at Nam Phong Community Hospital, Khon Kaen, Thailand; Ms. Surada Tantanugool, Dentist at Borabue Community Hospital, Maha Sarakham, Thailand; and The Oral and Maxillofacial Clinic and The Laser Clinic, Faculty of Dentistry, Khon Kaen University, Thailand. We confirm that each person and entity listed has granted their permission to be acknowledged in this document.

References

- Nagraj SK, Prashanti E, Aggarwal H, et al. Interventions for treating post-extraction bleeding. *Cochrane Database of Syst Rev* 2018.
- Krishnan B, Prasad GA, Madhan B, et al. Post-extraction bleeding complications in patients on uninterrupted dual antiplatelet therapy—a prospective study. *Clin Oral Investig* 2021;25:507-14.
- Cheng Y, Al-Arooomi MA, Al-Worafi NA, et al. Influence of inflammation on bleeding and wound healing following surgical extraction of impacted lower third molars. *BMC Oral Health* 2023;23.
- Shao X, Xu XM, Yang X, Ji AP. Analysis of Risk Factors for Post-Extraction Bleeding and Study on Emergency Intervention Strategies. *Risk Manag Healthc Policy* 2024;17:1279-86.
- Ueda K, Inokoshi M, Kubota K, et al. Factors influencing postoperative bleeding after dental extraction in older adult patients receiving anti-coagulation therapy. *Clin Oral Investig* 2024;28.
- Rubboli A. Incidence, clinical impact and risk of bleeding during oral anticoagulation therapy. *World J Cardiol* 2011;3.
- Li L, Zhang W, Yang Y, et al. Dental management of patient with dual antiplatelet therapy: a meta-analysis. *Clin Oral Investig* 2019;23.
- Sattayut S, Tanya S, Patcharanuchat P. Low-Intensity Laser Therapy Inducing Photobiomodulation for Oral Health Promotion of Older People in Primary Health Care Unit; Case Study. *J Gerontol Geriatr Med* [Internet] 2021;1:112-4. Available from: https://journalggm.org/article_pdf-PA21021.pdf
- Mahardawi B, Jiaranuchart S, Rochanavibhata S, et al. The role of hemostatic agents after tooth extractions: A systematic review and meta-analysis. *J Am Dent Assoc* 2023;154:742-52.e1.
- Ji J, Barrett EJ. Suspected intraoperative anaphylaxis to gelatin absorbable hemostatic sponge. *Anesth Prog* 2015;62.
- Ishikawa I, Okamoto T, Morita S, et al. Blue-violet light emitting diode (LED) irradiation immediately controls socket bleeding following tooth extraction; clinical and electron microscopic observations. *Photomed Laser Surg* 2011;29.
- Veleska-Stevkoska D, Koneski F. Haemostasis in oral surgery with blue-violet light. *Open Access Maced J Med Sci* 2018;6:687-91.
- Gaur S, Madhulaxmi M. Application of LED light of the Blue-Violet Spectrum to induce Haemostasis Post Therapeutic Extractions-A Prospective Study. *J Res Med Dent Sci* [Internet] 2021;9:202-5. Available from: <https://www.jrmds.in/articles/application-of-led-light-of-the-blueviolet-spectrum-to-induce-haemostasis-post-therapeutic-extractions-a-prospective-stud.pdf>
- Okamoto T, Ishikawa I, Kumasaka A, et al. Blue-violet light-emitting diode irradiation in combination with hemostatic gelatin sponge (Sponge) application ameliorates immediate socket bleeding in patients taking warfarin. *Oral Surg Oral Med Oral Pathol Oral Radiol* 2014;117.
- Malakam C, Sattayut S. A variety of photocoagulation techniques haemostasis in oral soft tissue and extraction socket. *Laser Magazine* [Internet] 2016;16-20. Available from: https://www.researchgate.net/publication/306399209_Photoagulation_for_hemostasis_in_soft_tissue_and_bone-socket_Case_reports
- Hamzah BF, Ibraheem NS. The effect of low-level laser therapy after simple tooth extraction. *J Int Oral Health* 2019;11:181.
- Kelkar M, Kadanthode M, Mohanty S, Verma A. Effect of low-level laser therapy on post-extraction hemostasis in patients with hemophilia — A prospective cohort study. *J of Craniomaxillofac Surg* 2023;51.
- Klangthong A, Sattayut S, Kantrong N, et al. Diode Laser-Mediated Photocoagulation in an Alveolar Socket after Tooth Extraction: A Preliminary Study. *Khon Kaen Dent J* [Internet] 2022;25:91-100. Available from: <https://he01.tci-thaijo.org/index.php/KDJ/article/view/244713/175055>
- Larionova EV, Diachkova EY, Morozova EA, et al. Laser-assisted tooth extraction in patients with impaired hemostasis. *BioMedicine (Taiwan)* 2021;11.
- Luo GY, Sun L, Wei EX, Tan X, Liu TC. The effects of low-intensity He-Ne laser irradiation on erythrocyte metabolism. *Lasers Med Sci* 2015;30:2313-8.
- Al Musawi MS, Jaafar MS, Al-Gailani B, et al. Erythrocyte sedimentation rate of human blood exposed to low-level laser. *Lasers Med Sci* 2016;31.
- Mi XQ, Chen JY, Liang ZJ, Zhou LW. In vitro effects of helium-neon laser irradiation on human blood: blood viscosity and deformability of erythrocytes. *Photomed Laser Surg* 2004;22:477-82.
- Hupp JR, Tucker MR, Ellis E. *Contemporary oral and maxillofacial surgery*. 7th ed. Philadelphia, Pa: Elsevier; 2019.
- Morkmued S, Tanya S, Sattayut S. Immediate Laser-Induced Coagulation after Tooth Extraction to Prevent Complications in Compromised Bleeding Tendency Patients (abstract). In: 15th International Conference of the Asian Academy of Preventive Dentistry, 8-11 Nov 2023, Hong Kong, Hong Kong, 2023.
- Dompe C, Moncrieff L, Matys J, et al. Photobiomodulation—underlying mechanism and clinical applications. *J Clin Med* 2020;9:1724.
- Hamblin MR. Mechanisms and mitochondrial redox signaling in photobiomodulation. *Photochem Photobiol* 2018;94:199-212.
- Wajih N, Alipour E, Rigal F, et al. Effects of nitrite and far-red light on coagulation. *Nitric Oxide* 2021;107:11-8.
- Walski T, Grzeszczuk-KuĆ K, Gałęcka K, et al. Near-infrared photobiomodulation of blood reversibly inhibits platelet reactivity and reduces hemolysis. *Sci Rep* 2022;12:1-12.
- Vladimirov YA, Gorbatenkova EA, Paramonov NV, Azizova OA. Photoreactivation of superoxide dismutase by intensive red (laser) light. *Free Radic Biol Med* 1988;5:281-6.