

**Therapeutic laser and neural mobilization in diabetic peripheral neuropathy: a case report**

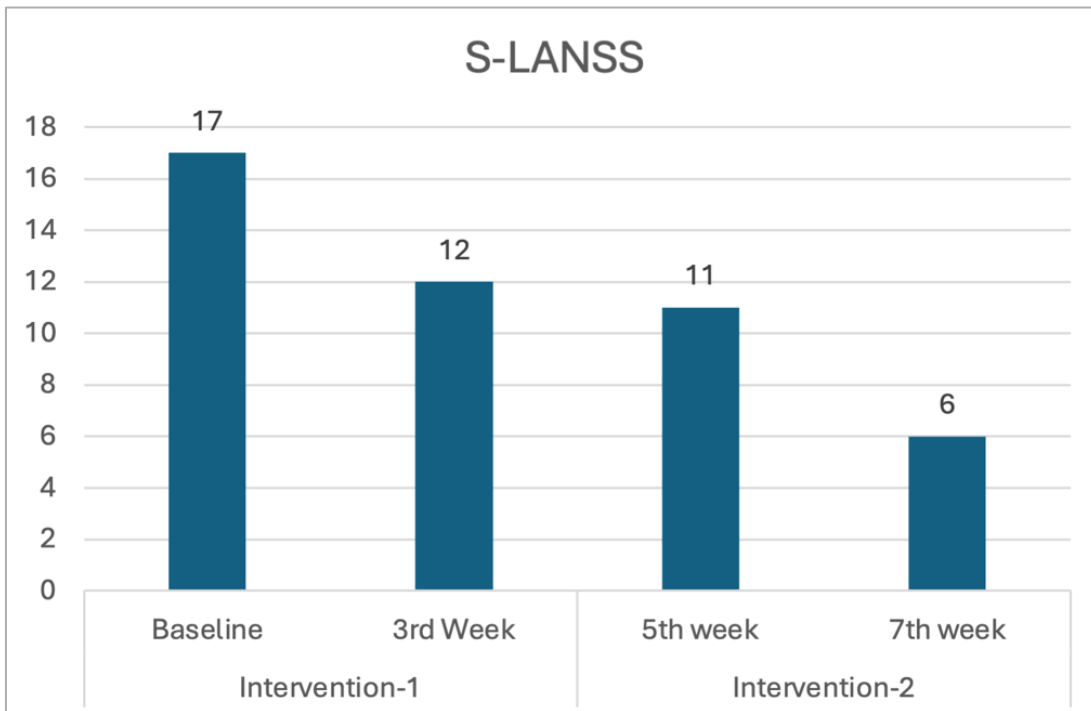
Rittu Sharma, Manu Goyal

*Maharishi Markandeshwar Institute of Physiotherapy and Rehabilitation, Maharishi Markandeshwar  
(Deemed to be University), Mullana, Haryana, India*

*doi: 10.4081/ljt.2026.430*

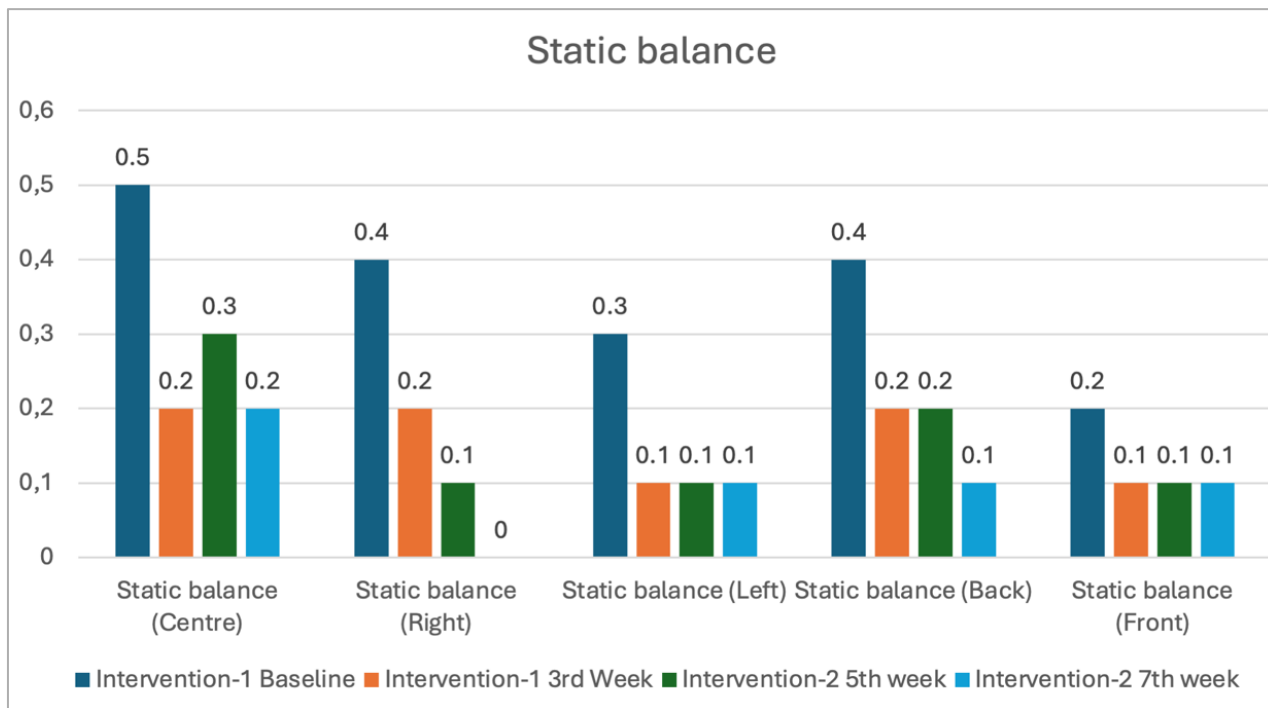
**SUPPLEMENTARY MATERIAL**

**Supplementary Figure 1.** Pre- and post-intervention values of S-LANSS.

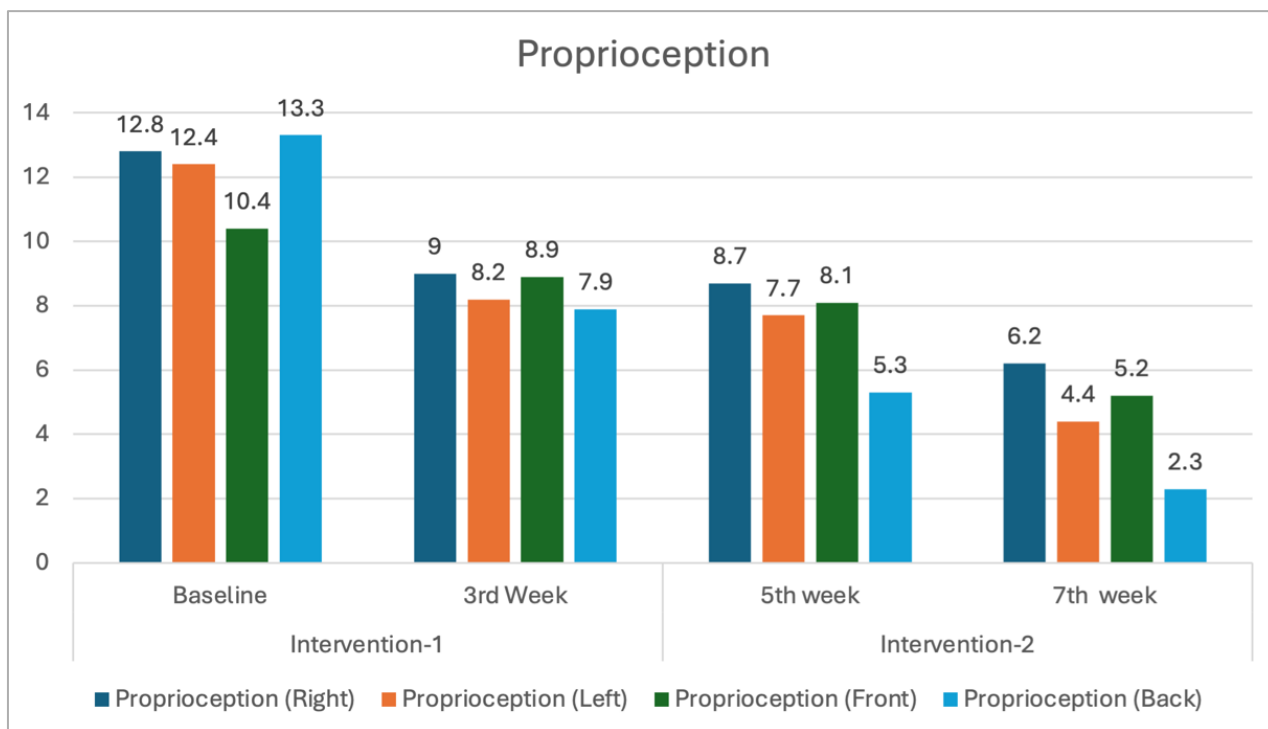


S-LANSS, Self-Administered Leeds Assessment of Neuropathic Symptoms and Signs.

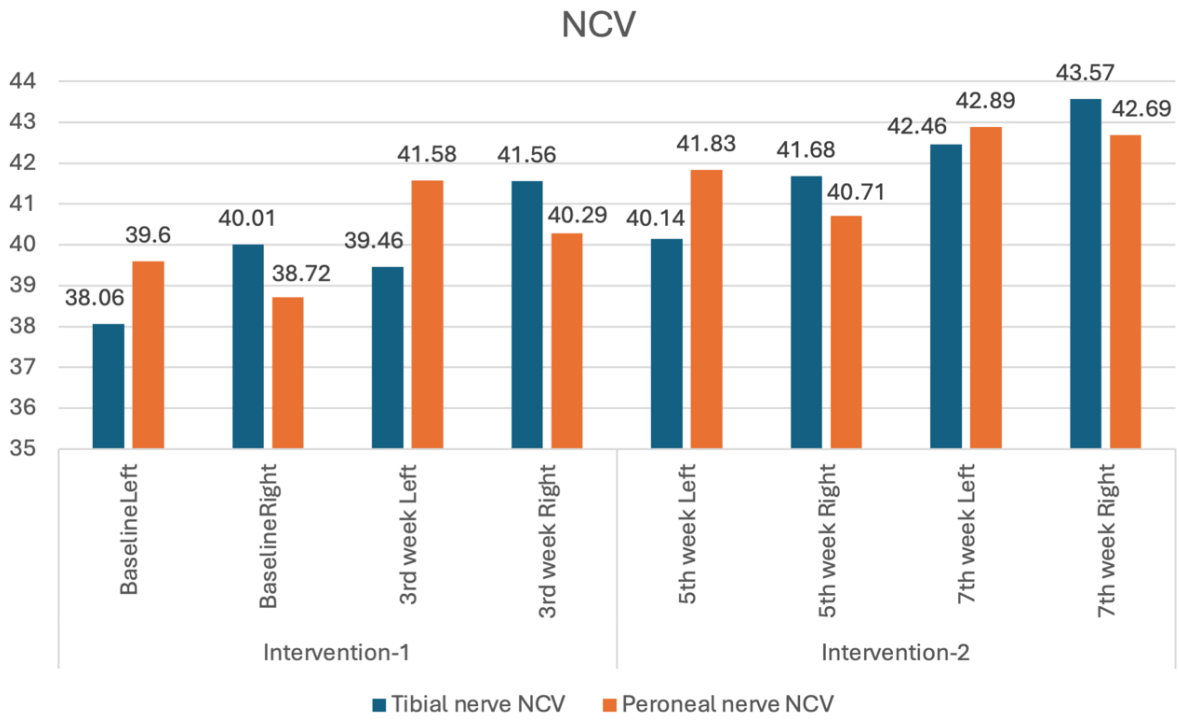
**Supplementary Figure 2.** Pre- and post-intervention values of static balance.



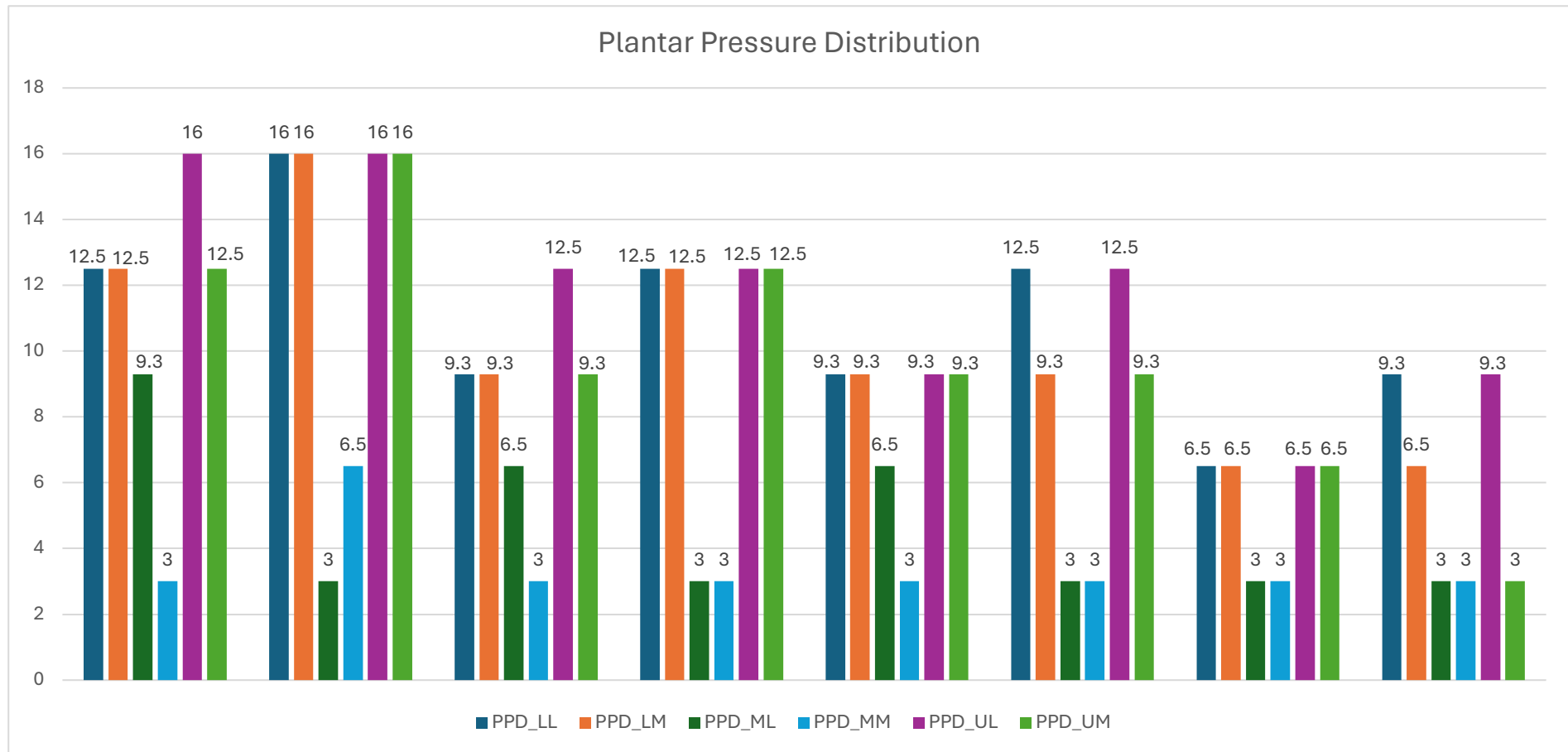
**Supplementary Figure 3.** Pre- and post-intervention values of proprioception.



**Supplementary Figure 4.** Pre- and post-intervention values of nerve conduction velocity.



**Supplementary Figure 5.** Pre- and post-intervention values of plantar pressure distribution.



PPD, plantar pressure distribution; LL, lower lateral; LM, lower medial; ML, middle lateral; MM, middle medial; UL, upper lateral; UM, upper medial.