
Therapeutic laser and neural mobilization in diabetic peripheral neuropathy: a case report

Rittu Sharma, Manu Goyal

Maharishi Markandeshwar Institute of Physiotherapy and Rehabilitation, Maharishi Markandeshwar (Deemed to be University), Mullana, Haryana, India

ABSTRACT

Diabetic peripheral neuropathy (DPN), a common complication of diabetes, leads to neuropathic pain, reduced nerve conduction, impaired balance, and abnormal plantar pressure, increasing the risk of falls and ulceration. Conventional therapies often provide limited relief, leaving persistent pain and dysfunction. Class IV laser therapy offers potent photobiomodulation to enhance nerve regeneration and conduction, while neural mobilization restores nerve dynamics. This case report highlights the therapeutic potential of class IV laser therapy as a key intervention for neurorehabilitation in DPN, used in conjunction with neural mobilization to enhance outcomes. The laser intervention resulted in marked alleviation of neuropathic pain and significant improvement in nerve conduction, balance, and proprioceptive control. Plantar pressure analysis demonstrated a more balanced load distribution, indicating optimized foot biomechanics and reduced ulceration risk. Overall, the findings underscore class IV laser therapy, particularly when integrated with neural mobilization, as a powerful, non-invasive physiotherapeutic approach capable of accelerating neural recovery and enhancing functional restoration in patients with DPN.

Key words: diabetic peripheral neuropathy; laser therapy; neuropathic pain; nerve conduction; neurorehabilitation.

Corresponding author:

Manu Goyal, Professor, Maharishi Markandeshwar Institute of Physiotherapy and Rehabilitation,
Maharishi Markandeshwar (Deemed-to-be-University), 133207 Mullana, Haryana, India.
E-mail: manu.goyal@mmumullana.org

Received: 27 October 2025.
Accepted: 15 December 2025.

Laser Therapy

©Copyright: the Author(s), 2026
Licensee PAGEPress, Italy
Laser Therapy 2026; 33:430
doi:10.4081/ljt.2026.430

Introduction

Diabetic peripheral neuropathy (DPN) is one of the most prevalent microvascular complications of diabetes, affecting approximately 70% of individuals with chronic diabetes. It is distinguished by sensory and motor impairments in a glove-and-stocking pattern caused by metabolic and vascular damage to peripheral nerves. These neuropathic changes cause pain, decreased nerve conduction velocity (NCV), proprioceptive loss, altered plantar pressure, and balance impairments, all of which increase the risk of falls and foot ulcers while reducing functional mobility and quality of life.¹⁻³ Neural mobilization and laser therapy have recently drawn attention for enhancing nerve function and sensorimotor execution in DPN.

Neural mobilization restores neural tissue dynamics by improving intraneural blood flow and axoplasmic transport, enhancing conduction and reducing mechanical sensitivity.^{3,4} Doshi *et al.*, and Sharma *et al.*, found that mobilizing the tibial and common peroneal nerves significantly enhanced NCV, balance, and gait in DPN patients.^{3,4} Conversely, class IV laser therapy, a high-intensity photobiomodulation, facilitates nerve regeneration and pain reduction through mitochondrial activation, adenosine triphosphate (ATP) synthesis, and enhanced microcirculation.^{5,6} Chatterjee *et al.*, demonstrated reduced neuropathic pain and increased quality of life with deep tissue laser therapy, while Kumar *et al.*, Bashiri, and Yamany *et al.*, found that low-level laser therapy enhanced sensorimotor outcomes.^{5,7-9}

Despite these promising results, literature on class-IV laser therapy in DPN remains limited, with no studies comparing or integrating it with neural mobilization. Most research has addressed pain or conduction improvements without examining functional parameters such as balance, proprioception, or plantar pressure distribution, key indicators of sensorimotor recovery and fall risk. Therefore, this case report provides novel evidence of improvements in neuropathic pain, NCV, balance, proprioception, and plantar pressure, underscoring the combined potential of these physiotherapeutic interventions in restoring peripheral nerve and functional integrity in DPN.

Case Report

A 45-year-old female presented to the physiotherapy outpatient department with persistent complaints of

burning sensations and pain in both lower extremities. The patient also reported a progressive loss of sensation in both lower limbs over the past nine months, along with restricted ankle mobility and worsening balance, resulting in increasing difficulty with ambulation over the past year. Her glycemic status showed an HbA1c level of 7.8%, indicating sub-optimal glycemic control. The patient has been on a stable anti-diabetic regimen since diagnosis, which includes metformin (500 mg twice daily after meals) and glimepiride (1 mg once daily post-breakfast). There was no family history of diabetes, suggesting a sporadic onset. Overall, the clinical presentation was consistent with DPN involving both motor and sensory components, which further exacerbated her functional limitations and increased her risk of falls.

Clinical findings

Upon a comprehensive clinical assessment, the patient displayed typical DPN symptoms. These included persistent neuropathic pain with burning and tingling sensations, as well as significant abnormalities in balance and proprioception, indicating compromised sensory feedback pathways. Furthermore, an evident shift in plantar pressure distribution was observed, indicating asymmetrical foot loading. Neurophysiological studies confirmed these findings, exhibiting lower NCV in both the tibial and common peroneal nerves, indicating peripheral nerve dysfunction. Collectively, these findings highlight the intricate interplay between sensory and motor impairments in DPN, which contributes to reduced functional mobility and reduced overall quality of life. Table 1 illustrates the study timeline.

Diagnostic assessment

The patient was assessed using a comprehensive set of outcome measures to evaluate the neuropathic pain, balance, proprioception, plantar pressure distribution, and peripheral nerve function.

Neuropathic pain was assessed using the Self-Leeds Assessment of Neuropathic Symptoms and Signs (S-LANSS), where a score ≥ 12 indicates neuropathic symptoms.¹⁰ Peripheral nerve function was evaluated using NCV testing of the tibial and common peroneal nerves. Measurements were performed with the Neuro-

pack S3 MEB-9600 V02-03 (C) 2018 system (Nihon Kohden Co., Japan). Motor conduction velocities <50 m/s were indicative of diminished nerve conduction, confirming peripheral neuropathy.² Balance and proprioception were assessed using the Pedalo[®]-Sensamove Balance Test Pro with Miniboard. Static balance was measured in five positions, and proprioception in four directions. Lower scores (in degrees) indicated better directional awareness and proprioceptive control.^{2,11} Plantar pressure mapping was performed using a Harris mat placed mid-walkway (5 m). As the patient walked, foot imprints were left on the mat and analyzed *via* Podia Scan software (N/cm²). Lower scores reflected more optimal and evenly distributed plantar pressure. Altered plantar pressure, a known risk factor for foot ulcers in DPN, was evident in this case.^{1,12}

Interventions

After obtaining informed consent, the patient underwent a structured physiotherapy intervention. Intervention 1 consisted of neural mobilization of the tibial and common peroneal nerves, performed in 3 sets of 30 repetitions (15 sliders and 15 tensioners) over 2 minutes, followed by a 1-minute rest interval, administered 4 times per week for 3 weeks (Figures 1 and 2). A one-week washout period was incorporated between the two intervention phases to minimize potential carry-over effects. Intervention 2 included class-IV laser therapy. Nerve irradiation was administered bilaterally over the popliteal fossa, around the fibular neck, 5 cm above the medial malleolus, and on the plantar surface of the foot, for a total duration of 12 minutes per session, 4 times per week for 3 weeks (Figure 3).^{1,5,13}

Neural mobilization techniques

Tibial nerve

- i) Remote sliders: the physiotherapist initially positioned the ankle in dorsiflexion and eversion, followed by passive hip flexion while carefully monitoring for any onset of pain or symptoms. The hip was then lowered to a pain-free range. Subsequently, the therapist alternated between flexing the knee (to unload the tibial nerve) while maintaining ankle dorsiflexion and eversion, and extending the knee (to load the tibial nerve) while allowing the ankle to move into plantarflexion (unloading the tibial nerve).
- ii) Local sliders: the physiotherapist began by positioning the ankle in dorsiflexion and eversion, followed by passive hip flexion while maintaining knee extension, carefully observing for the appearance of any pain or symptoms. The hip and knee were then lowered to a point just before the onset of any symptoms. After that, the physiotherapist performed alternated movements, flexing the hip (to unload the tibial nerve) while dorsiflexing and everting the ankle (to load the tibial nerve), and then extending the hip (to load the tibial nerve) while moving the ankle into plantarflexion (to unload the tibial nerve) (Figure 1).
- iii) Tensioners: the physiotherapist elevated the patient's leg from the table with the knee extended and the hip flexed. The ankle was then moved into dorsiflexion and eversion to load the tibial nerve, followed by returning it to plantarflexion to unload the nerve (Figure 2).¹

Table 1. Timeline of the study.

Event	Timeline
Pre-assessment	Conducted on the first day of the patient's presentation
Physiotherapy treatment Intervention 1: neural mobilization	Neural mobilization was administered involving both sliders and tensioners of tibial and common peroneal nerve; 4 times/week for 3 weeks
Post-intervention assessment	Conducted at the end of the 3 rd week from the start of treatment
Washout period of 1 week Schedule at the 4 th week from the start of treatment	
Pre-assessment	Conducted on the first day of 5 th week from the start of the treatment
Physiotherapy treatment Intervention 2: laser therapy	Laser therapy was administered at 5 cm above the medial malleolus, over the popliteal fossa and neck of the fibula, and plantar surface of the feet; 4 times/week for 3 weeks
Post-intervention assessment	Conducted at the end of the 7 th week from the start of treatment

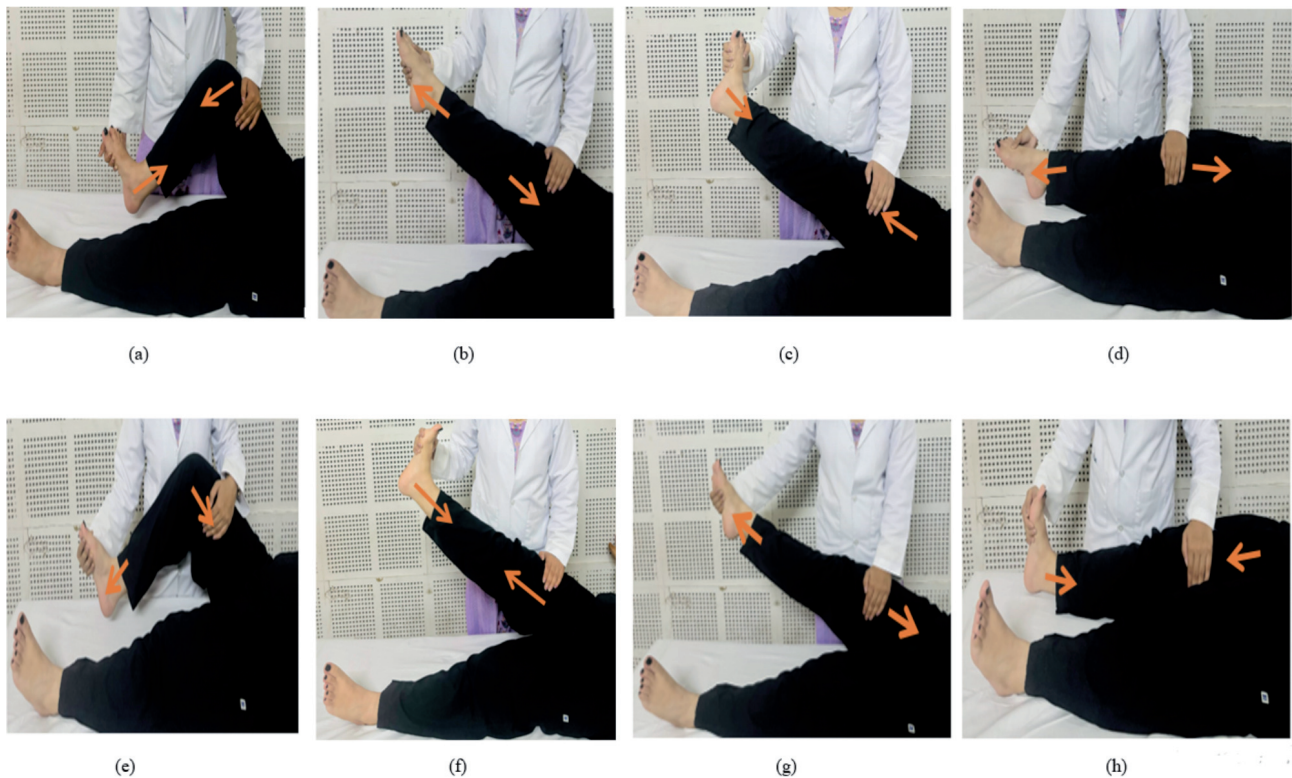


Figure 1. Sliders of the tibial nerve (a-d) and common peroneal nerve (e-h).

Common peroneal nerve

- i) Remote slider: The physiotherapist began by positioning the ankle in plantarflexion and inversion, followed by passive hip flexion while carefully monitoring for the appearance of any pain or symptoms. The hip was then adjusted to a position within the pain-free range. Afterward, the therapist alternated between flexing the knee (to unload the peroneal nerve) while maintaining ankle plantarflexion and inversion (to load the peroneal nerve), and extending the knee (to load the nerve) while moving the ankle into dorsiflexion (to unload it) (Figure 1).
- ii) Local slider: The physiotherapist initiated the movement by keeping the ankle in plantarflexion (PF) and inversion, then passively flexed the hip while keeping the knee extended, observing for any signs of pain or discomfort. The hip and knee were positioned in a range that remained symptom-free. The therapist then flexed the hip (unloading) while maintaining the ankle in plantarflexion and inversion (loading),

followed by extending the hip (loading) with the ankle dorsiflexed (unloading) (Figure 1).

- iii) Tensioners: With the hip flexed and knee extended, the physiotherapist elevated the patient's leg off the table and performed ankle plantarflexion (PF) and inversion to load the peroneal nerve, then returned the ankle to dorsiflexion to unload it (Figure 2).¹

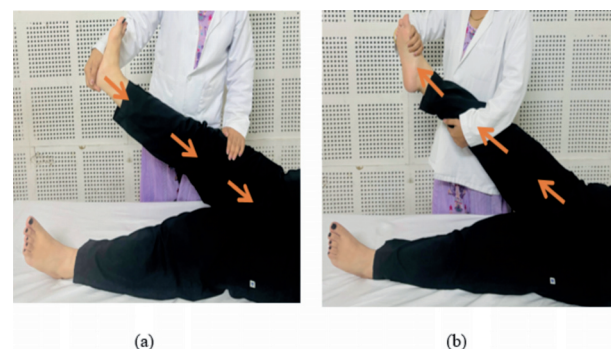


Figure 2. Tensioners of the tibial nerve (a) and the common peroneal nerve (b).

Class-IV laser therapy

Class-IV laser therapy was administered bilaterally over the popliteal fossa, neck of fibula, medial malleolus, and plantar surface of the foot using a grid-based technique to ensure uniform energy distribution. The treatment was delivered in a non-contact mode with continuous (non-pulsed) beam emission using a Lite-Cure Gallium-Aluminum-Arsenide (GaAlAs) near-infrared laser device (Lite Cure, LCT-1000C Therapy Laser, Model number LCT-1000C). The dosage parameters included a wavelength of 980 nm, power 8 W, and an energy density ranging from 10-20 J/cm², administered at a constant speed of 1 cm/s for a total duration of 12 minutes (6 minutes to each side).

For each popliteal fossa, covering an area of approximately 20 cm², nerve irradiation was performed using a 980 nm wavelength laser with a power output of 8 W and an irradiance of 0.4 W/cm². The treatment was applied for 45 seconds, delivering a total energy of 360 J, corresponding to a fluence of 18 J/cm².

For the neck of the fibula, the nerve was irradiated over a 9 cm² area with the same wavelength, power, and technique used for the popliteal fossa. The irradiance was 0.8 W/cm², and the treatment was delivered for 15 seconds per session, resulting in a dose of 126 J corresponding to 14 J/cm².

Nerve irradiation around the medial malleolus covered an area of about 15 cm² using the same wavelength, power, and method as for the popliteal fossa treatment. The irradiance was 0.5 W/cm², and the treatment lasted for 30 seconds, delivering a dose of 240 J at 16 J/cm² per session.

Each plantar surface, which covered an area of 126 cm², was treated using the same wavelength, power, and method as for the popliteal fossa treatment, with an irradiance of 0.07 W/cm². The treatment was given for 4.5 minutes, delivering the dose of 2142 J/cm² at 17 J/cm² to each plantar surface (Figure 3).^{5,13}

Follow-up and outcomes

In this case, various outcome measures were employed to evaluate the effectiveness of interventions before and after completion of each intervention (baseline, 3rd, 5th, and 7th week). The pre- and post-intervention scores, detailed in *Supplementary Figures 1-5*, clearly reflect the participant's progressive improvements. Noteworthy

gains were observed in neuropathic pain reduction, enhanced nerve conduction velocity, improved static balance and proprioception, as well as more optimal plantar pressure distribution. These findings highlight the positive and cumulative impact of the therapeutic interventions over time.

Discussion

This case report presents evidence that integrating neural mobilization and class-IV laser therapy for addressing multiple impairments in DPN, including neuropathic pain, reduced NCV, altered proprioception, balance dysfunction, and uneven plantar pressure. The observed improvements highlight the contribution

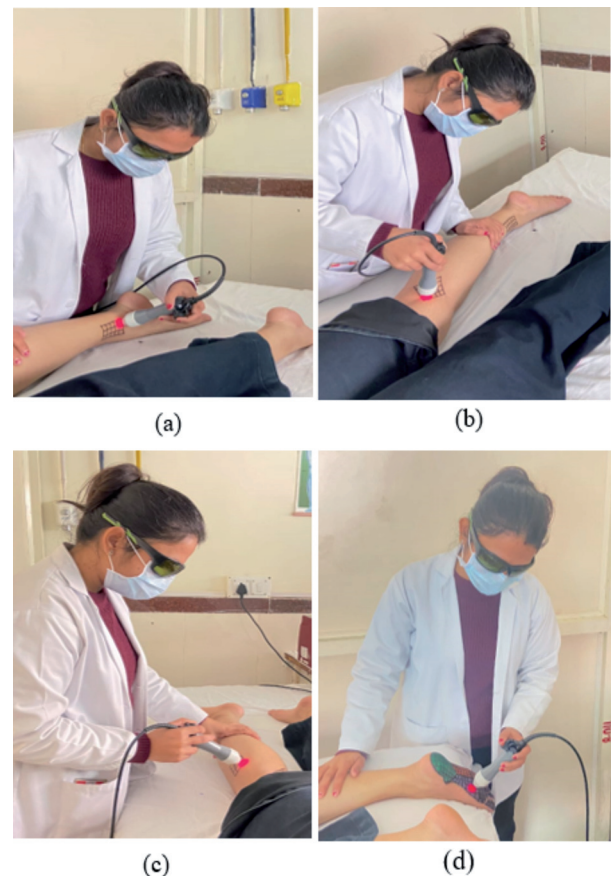


Figure 3. Nerve irradiation at 5 cm above the medial malleolus (a), popliteal fossa (b), neck of fibula (c), and plantar surface of the foot (d).

of these interventions in enhancing neuronal integrity and sensorimotor function.

Notable improvements in NCV and pain reduction were observed following tibial and common peroneal nerve mobilization, consistent with the findings of Doshi *et al.* and Sharma *et al.*, who reported that peripheral nerve mobilization enhances intraneural circulation and axoplasmic transport while reducing neural stress.^{4,3}

Subsequent class-IV laser therapy further enhanced outcomes through deep tissue photobiomodulation and produced photobiomodulatory effects, stimulating mitochondrial energy production, improving local circulation, and promoting neural tissue regeneration. These results are consistent with the findings of Chatterjee *et al.*, who demonstrated that deep tissue laser can effectively alleviate neuropathic pain and improve quality of life.⁵

Improvements in balance and proprioception measured *via* Pedalo®-Sensamove Balance Test reflect restored afferent feedback and postural control through enhanced nerve conduction and sensory integration. Although limited studies have assessed these parameters in DPN, Ahmad *et al.* confirmed the test's reliability for detecting proprioceptive deficits, supporting the present findings.^{2,11} These results provide novel evidence that physiotherapeutic interventions can effectively enhance functional stability in diabetic neuropathy. Enhanced plantar pressure distribution following treatment indicates improved foot biomechanics and load symmetry, which are clinically relevant for reducing the risk of ulceration and falls. Similar conclusions have been reported by Goyat *et al.* and Welton, emphasizing the importance of balanced plantar loading in preventing diabetic foot complications.^{1,12}

The sequential application of neural mobilization followed by laser therapy may have exerted a synergistic effect, wherein mobilization optimized neural mechanics and perfusion, thereby improving tissue responsiveness to photobiomodulation. This integrative approach likely contributed to the cumulative improvements observed across all parameters. Although based on a single case, these findings highlight the potential of combining mechanical and photobiological interventions for comprehensive DPN rehabilitation. Larger randomized controlled trials are needed to validate these results and standardize treatment protocols.

Conclusions

Neural mobilization and class-IV laser therapy demonstrated distinct benefits, and when applied sequentially, produced synergistic effects that enhanced neural recovery and functional outcomes in DPN. This case emphasizes the potential of combining mechanical and photobiomodulation strategies in neurorehabilitation and underscores the need for further validation through larger clinical studies.

Contributions: Rittu Sharma: conceptualization, data analysis and interpretation, writing – original draft preparation, writing – review & editing; Manu Goyal: conceptualization, data analysis and interpretation, writing – review & editing. All authors read and approved the final version of the manuscript and agreed to be accountable for all aspects of the work.

Conflict of interest: the authors have no conflict of interest to declare.

Ethics approval and consent for publication: no ethical committee approval was required for this case report by the Department, because this article does not contain any studies with human participants or animals. The patient provided informed consent to participate.

Informed consent: the patient provided written informed consent for the publication of this case report and any accompanying images.

Availability of data and materials: all data underlying the findings are available from the authors upon reasonable request.

Funding: this study received no specific funding.

Acknowledgments: the authors express their gratitude to the authors of the cited articles for their contributions to the supporting evidence.

References

1. Goyat M, Saxena A, Goyal M. Study Protocol titled as "Effectiveness of neural mobilization in improving the ankle ROM and plantar pres-

- sure distribution in patients with diabetic peripheral neuropathy: A single group, pre post, quasi experimental study protocol". *J Diabetes Metab Disord* 2022;21:2035-41.
2. Thakur K, Goyal M. Effectiveness of Neuromuscular Taping on Balance, Proprioception, Pain, and Nerve Conduction Parameters in Patients with Diabetic Peripheral Neuropathy: A Two-Group Pretest-Posttest Randomized Sham-Controlled Trial: A Pilot Study. *J Diabetol* 2024;15:367-73.
 3. Sharma S, Kalia V. Effect of tibial nerve mobilization on balance & gait functions in subjects with subclinical diabetic neuropathy: A randomized clinical trial. *J Diabetes Metab Disord* 2023;22:1283-90.
 4. Doshi MK, Singaravelan RM. Effect of tibial nerve mobilization on nerve conduction velocity in diabetic polyneuropathy patients. *Int J Heal Sci Res* 2019;9:218-24.
 5. Chatterjee P, Srivastava AK, Kumar DA, et al. Effect of deep tissue laser therapy treatment on peripheral neuropathic pain in older adults with type 2 diabetes: A pilot randomized clinical trial. *BMC Geriatr* 2019;19:1-10.
 6. Khadayat S, Kumar A. Efficacy of Class IV LASER Therapy and Sensory Re-education in Patients with Diabetic Neuropathy: A Case Report. *J Diabetol* 2025;16:83-6.
 7. Kumar S, Maiya AG, Manjunath H, et al. Efficacy of low level laser therapy on painful diabetic peripheral neuropathy. *Laser Ther* 2015;24:195-200.
 8. Bashiri H. Evaluation of low level laser therapy in reducing diabetic polyneuropathy related pain and sensorimotor disorders. *Acta Med Iran* 2013;51:543-7.
 9. Yamany AA, Sayed HM. Effect of low level laser therapy on neurovascular function of diabetic peripheral neuropathy. *J Adv Res* 2012;3:21-8.
 10. Bennett MI, Smith BH, Torrance N, Potter J. The S-LANSS score for identifying pain of predominantly neuropathic origin: Validation for use in clinical and postal research. *J Pain* 2005;6:149-58.
 11. Ahmad I, Noohu MM, Verma S, et al. Validity and Responsiveness of Balance Measures using Pedalo@-Sensomove Balance Device in Patients with Diabetic Peripheral Neuropathy. *J Clin Diagnostic Res* 2019;13:YC01-4.
 12. Welton EA. The Harris and Beath footprint: Interpretation and clinical value. *Foot Ankle* 1992;13:462-8.
 13. Baxter D, Nussbaum EL. Chapter 10: Laser. Watson T, Nussbaum EL., editor. *Electrophysical agents: Evidence-based practice*. Thirteenth edition. Elsevier, 2021, p. 189-205.

Online supplementary material:

Supplementary Figure 1. Pre- and post-intervention values of S-LANSS.

Supplementary Figure 2. Pre- and post-intervention values of static balance.

Supplementary Figure 3. Pre- and post-intervention values of proprioception.

Supplementary Figure 4. Pre- and post-intervention values of nerve conduction velocity.

Supplementary Figure 5. Pre- and post-intervention values of plantar pressure distribution.